

# Pathoepidemiology of Epstein-Barr virus infection and peculiar necrosis in nasal NK/T-cell lymphomas in northeast China.

著者	Hasui Kazuhisa, Wang Jia, Jia Xinshan, Matsuyama Takami, Izumo Shuji, Kawano Yoshifumi, Kanekura Takuro, Eizuru Yoshito, Aozasa Katsuyuki
journal or publication title	Proceedings of The 10th Japanese-Korean Lymphoreticular Workshop 2009 and Symposium: Asian Hematopathology
page range	40-42
URL	<a href="http://hdl.handle.net/10232/10017">http://hdl.handle.net/10232/10017</a>

## O9

### **PATHOEPIDEMIOLOGY OF EPSTEIN-BARR VIRUS INFECTION AND PECULIAR NECROSIS IN NASAL NK/T-CELL LYMPHOMAS IN NORTHEAST CHINA**

Kazuhisa Hasui<sup>1</sup>, Wang Jia<sup>1</sup>, Xinshan Jia<sup>2</sup>, Takami Matsuyama<sup>1</sup>, Shuji Izumo<sup>1</sup>, Yoshifumi Kawano<sup>1</sup>, Takuro Kanekura<sup>1</sup>, Yoshito Eizuru<sup>1</sup> and Katsuyuki Aozasa<sup>3</sup>,

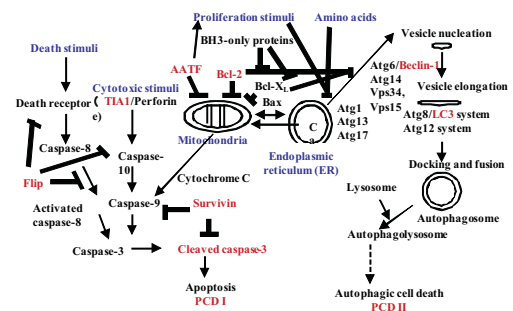
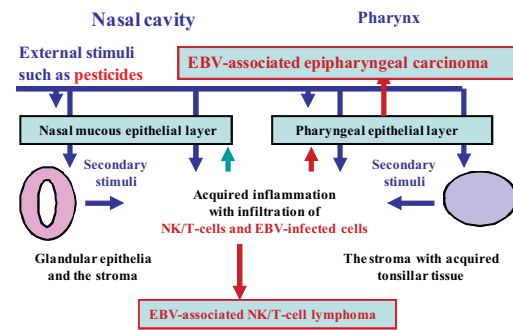
<sup>1</sup>Kagoshima University, Kagoshima, Japan, <sup>2</sup>Department of Pathology, China Medical University, Shenyang, China, <sup>3</sup>Department of Pathology, Osaka University, Osaka, Japan

Abstract : Nasal NK/T-cell lymphoma (NKTCL) is an Epstein-Barr virus (EBV)-associated lymphoma when the close relationship between nasal NKTCL in Japan and EBV infection was elucidated by Harabuchi et al (Lancet, 1990) and the EBV infection in NKTCL is of Latency II (Takahara et al. Human Pathol. 2004). Recently predominant occurrence of nasal NKTCL was observed in China, even in the northeast region (Zhonghua Bing Li Xue Za Zhi. 2007). This study analyzed pathoepidemiologically EBV infection in 134 cases of nasopharyngeal lymphomas diagnosed clinically in the northeast China and investigated immunohistochemically peculiar necrosis in 40 cases of nasopharyngeal lymphomas. Most of 85 cases of T/NK-cell neoplasms (T-ML) were so-called nasal NKTCL comprising 5 cases of early NKTCL (Polymorphous reticulosis: PR), 65 cases of NKTCL and 9 cases of cytotoxic T-cell lymphomas. 24 of 35 cases of B-cell lymphomas (B-ML) were of diffuse large B-cell lymphoma (DLBCL) and 9 cases of small cancers were seen. Frequent occurrence of NKTCL in nasal cavity and in male and frequent occurrence of B-ML in pharynx, and their rare occurrence of B-ML under 40 years of Age were significant. 71 cases of NKTCL were EBV-associated when 5 cases were not and lymphoma cells with and without EBV infection were noted in the others. In the residual epithelial lesions in 26 cases of T-ML and 7 cases of B-MLs there were EBV-not-associated and survivin-positive minute squamous carcinoma in 11 cases of EBV-associated NKTCL. EBV-associated NKTCL revealing peculiar necrosis did not show cleaved caspase-3-positive apoptotic lymphoma cells and expressed survivin, different from the previous reports based on so-called cell line research (Jeon et al., Ko et al. Lab Invest. 2005, 2007), expressed Beclin-1 (Atg6) and showed macrogranular staining of LC3 (Atg8), suggesting elevated autophagy. In the peculiar necrosis with naked nucleus-like cell debris, dense nuclear/peri-nuclear staining of LC3 was a hallmark of autophagic cell death. Consequently, EBV-not-associated NKTCL cells and minute squamous carcinoma in the NKTCL suggested microenvironmental factors other than EBV in the occurrence of NKTCL as suggested epidemiologically (Xu et al. Int J Cancer. 2007).

This presentation is concerned with EBV infection and programmed cell death in nasal NK/T-cell lymphomas in one of the endemic areas, northeast China. We investigated 134 archival specimens of nasopharyngeal lymphomas in Dept. of Pathol., China Medical University that locates in Shenyang, Northeast China.

In the nasopharynx, under external stimuli such as pesticide, EBV-associated nasopharyngeal carcinoma and lymphoma occur. And NKTCL associates pseudoepitheliomatous hyperplasia of covering squamous epithelia and shows peculiar necrosis. However, their occurrence and programmed cell death (PCD) had not yet clarified.

This study aimed to see their occurrence and programmed cell death by means of histochemical methods that can be applied to the archival specimens, such as EBV-encoded small RNA-1 in-situ hybridization (EBER-1 ISH), pH-independent antigen retrieval (AR)-polymer method of survivin for detecting neoplastic cells and suppression of apoptosis, and enzymatic AR-supersensitive method of beclin-1 in the autophagy initiation phase and pH-independent AR-polymer method of LC3 in the autophagic vesicles besides the routine method.



A representative NKTCL shows CD3 $\epsilon$ <sup>+</sup> TIA-1<sup>+</sup> CD56<sup>+</sup> lymphoma cells with a meshwork of CD204<sup>+</sup> macrophages. Most of lymphoma cells reveal EBER-1 signals in their nuclei. In an early NKTCL/polymorphous reticulosis (PR), survivin-positive NKTCL cells show sinusoidal distribution in the reticular lymphoid tissue rich in CD79a<sup>+</sup> B-cells and reveals small and large EBER-1 nuclear stain. A representative EBV-associated NKTCL associates pseudoepitheliomatous hyperplasia of the covering squamous epithelia. The squamous epithelia were positive for survivin and mostly free from EBV infection when some survivin-positive tissue stem cells are seen in the hyperplastic epithelia, thus they were EBV-free very minute squamous cell carcinoma (SCC). And small NKTCL cells under the SCC were also positive for survivin and free from EBV infection. Then, the precursor NKTCL and NKTCL-associating epithelial lesions would be caused by the factors other than EBV infection.

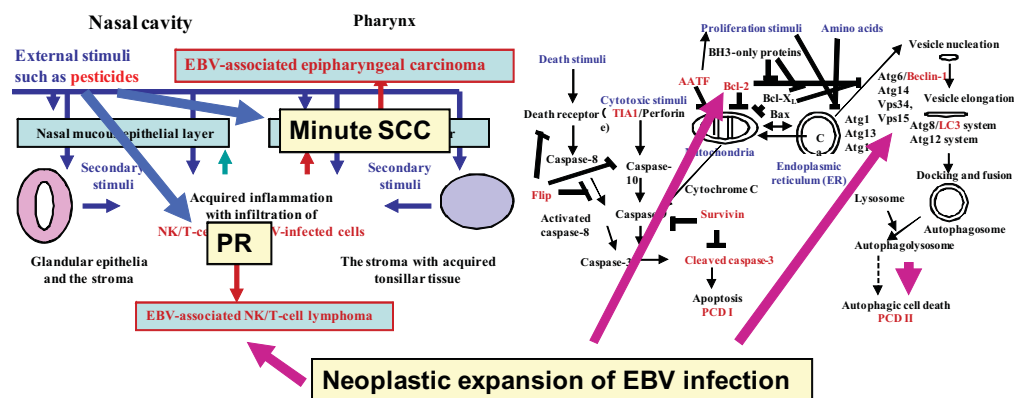
In the NKTCLs, most cases showed many EBER-1-positive nuclei, some cases revealed some EBER-1-positive nuclei and a few cases indicated a few or no EBER-1 positive nuclei. Then, we evaluated neoplastic expansion of EBV infection in NKTCL. This tendency was noted also in EBV-associated B-cell lymphomas. So-called SCC was found only in NKTCL beside nasopharyngeal cancers. Since many SCCs were free from EBV infection, the same oncogenic external factors were postulated also to induce NKTCL and SCC in the nasopharynx.

Developed meshwork of CD204<sup>+</sup> macrophages were found only in NKTCL, suggesting their symbiotic nature in NKTCL.

On the other hand, NKTCL shows degenerative tendency and peculiar necrosis. In such cases of

NKTCL, lymphoma cells locate around blood vessels in the degenerated background. The peculiar necrosis in NKTCL reveals naked nucleus-like cell debris in the eosinophilic necrotic tissue, different from that in circulatory disorders. The cases with the necrosis other than that of circulatory disorders were frequently seen in NKTCL and in one EBV-associated DLBCL. Then, the necrosis other than that of circulatory disorders was thought to be the event in EBV-associated cases of lymphomas, including NKTCL.

In representative NKTCL, cleaved caspase-3 was not expressed in both cellular and degenerative areas, when its neoplastic antagonist, survivin, was expressed strongly. And the antagonists of apoptosis signals, Flip and Bcl-2, were not expressed strongly. Apoptosis in the lymphomas was suppressed by the neoplastic expression of survivin. Bcl-2 suppression was noted in EBV-associated lymphomas. On the other hand, beclin-1 and LC3 were expressed strongly, suggesting accelerated autophagic vesicle nucleation and elongation. The change in LC3 staining pattern was obvious in the degenerative and degenerated areas. The nuclear stain of LC3 suggested advance in the autophagy in the necrosis. The nuclear stain of LC3 is the flag of autophagic cell death. Advance in autophagy and autophagic cells death labeled by LC3 seemed characteristic in EBV-associated lymphoma. The PCD in the representative case of NKTCL was of the autophagic cell death, PCD II.



The external stimuli would induce PR and minute SCC. In PR, NKTCL develops with neoplastic expansion of EBV infection. The EBV infection suppresses Bcl-1 that suppresses beclin-1. Then, acceleration of autophagy was induced and ended in autophagic cell death, PCD II, namely peculiar necrosis in EBV-associated lymphomas.

The content of this presentation appeared in Journal of Clinical and Experimental Hematopathology (JCEH).

Wang J, Hasui K, Jia XS, Matsuyama T, Eizuru Y. Possible Role for External Environmental Stimuli in Nasopharyngeal NK/T-Cell Lymphomas in the Northeast of China with EBV Infection-Related Autophagic Cell Death: A Pathoepidemiological Analysis. JCEH 2009; 49(2): 97-108.