

A Case Suggested as Eosinophilic Gastroenteritis with Ascites in a Young Patient

著者	WATANABE Teruhiko, ISHIGAMI Sumiya, SAIHARA Tetsushi, NATSUGOE Shoji
journal or publication title	鹿児島大学医学雑誌=Medical journal of Kagoshima University
volume	63
number	2
page range	37-41
別言語のタイトル	腹水を伴った若年者の好酸球性胃腸炎の1例
URL	http://hdl.handle.net/10232/14461

A Case Suggested as Eosinophilic Gastroenteritis with Ascites in a Young Patient

Teruhiko Watanabe MD¹⁾, Sumiya Ishigami MD, PhD¹⁾,
Tetsushi Saihara MD, PhD²⁾ Shoji Natsugoe MD, PhD¹⁾

¹⁾Department of Surgical Oncology and Digestive Surgery, Kagoshima University
School of Medicine, ²⁾Department of Surgery, Soo County Medical Hospital
(Accepted 28 February, 2011)

Abstract

We report a case of 13-year-old boy suggested as eosinophilic gastroenteritis (EG). He was admitted about fifteen months ago with abdominal pain and diarrhea. Laboratory test revealed remarkable elevation of eosinophilic count. Computed tomography and ultrasonography revealed thickness of the intestine and ascites. Upper and lower endoscopy findings were almost normal, and biopsy specimens did not reveal infiltrate of eosinophils. After excluding the possibilities of an inflammatory disease, parasitic disease, autoimmune disease and hypereosinophilic syndrome, he was suggested as having EG of the predominant subserosal layer. Steroid therapy was markedly effective. EG is a rare disorder characterized by eosinophilic infiltration of the gastrointestinal tissues. The etiology of EG is still unknown, but much research has been done in recent years regarding the molecular progression. Steroid therapy is the mainstay of the management of the disorder. When a patient with abdominal complaints is consulted, it is very important to keep this disease in mind.

Key words: eosinophilic gastroenteritis, predominant subserosal layer, steroid, ascites.

Introduction

EG was first described by Kaijser¹⁾ in 1937. This disorder, which is rare, can present with eosinophilic infiltration of the gastrointestinal tissues and various symptoms. Klein et al.²⁾ classified this disease into three types: mucosal, muscle, and subserosal layer. The predominant subserosal layer type is the rarest, found in only about 10% of the cases, and is typically manifested as ascites with an eosinophilic-rich content. We encountered a case with ascites and marked eosinophilia. Definite diagnosis by specimens was not done. After the possibilities of parasitic disease, etc. were eliminated, EG was exclusively suggested.

Case Report

A 13-year-old Japanese boy was referred and admitted about fifteen months ago with recurrent abdominal pain and watery diarrhea. He had suffered from the symptoms over the previous month. There had not been exposure to raw food. He had no history of allergic diathesis. Physical examination revealed that his abdomen was slightly distended. Laboratory tests revealed elevation of white blood cell and eosinophilic count at 9100 / μ l and 2157 / μ l (23.7%), respectively. Computed tomography revealed moderate ascites and marked thickening of intestinal wall (Fig. 1). Main findings of ultrasonography were similar to those of CT (Fig. 2). There were no involvements of the lung, kidney, or cardiovascular systems. The stools were negative for parasites. The IgE level was 111.7 U/

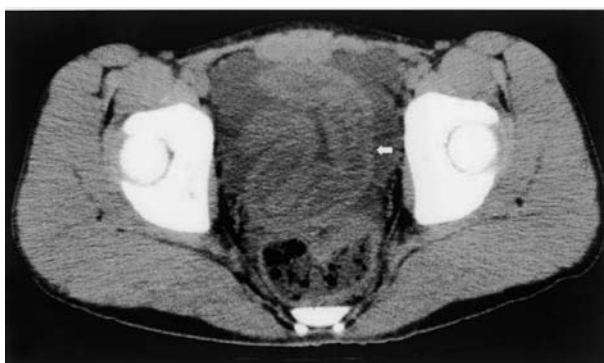


Fig. 1. Abdominal computed tomography revealed moderate quantities of ascites and wall thickness of intestine (arrow).

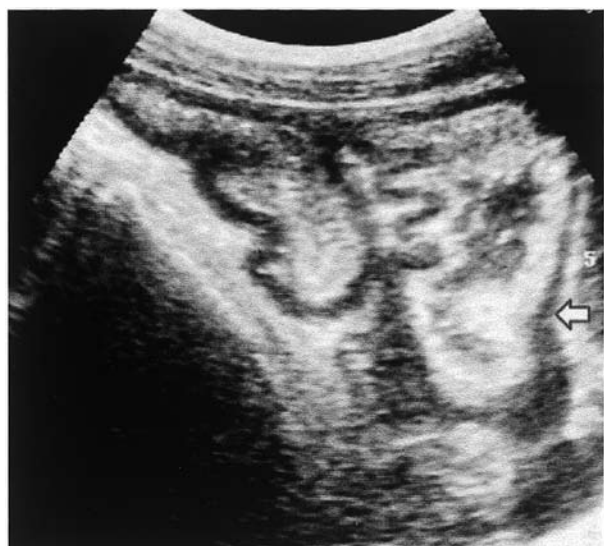

Fig. 2. Abdominal sonography indicated wall thickness of the bowel (arrow), as in the findings of the CT.

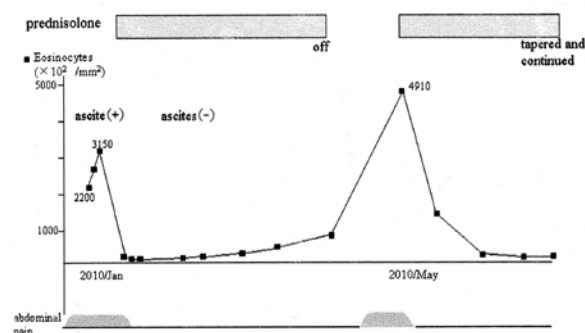


Fig. 3. Clinical course of case.

ml (normal range:0–250) and the main allergen-specific IgE antibodies were normal. Indices of inflammation and of autoimmune diseases were normal. Other laboratory studies were within the normal limit (Table 1). Upper and lower endoscopy findings were macroscopically normal. Endoscopic biopsy specimens of antral mucosa and ceacal mucosa did not reveal infiltrate of eosinophils. The volume of ascites was not much. Taking into account the risk of puncturing the abdominal cavity, we did not cytologically examine the ascites. Parasitic disease was deniable because the stools were negative for parasites. With no evidence of extra-intestinal disease, the possibility of hypereosinophilic syndrome was eliminated. According to the criteria of Talley et al.³⁾, the boy was suggested as having EG of the predominant subserosal layer. Oral 60mg/day prednisolone therapy was started and his symptoms were immediately relieved. The eosinophil count immediately decreased to normal range

Table 1. Laboratory findings on admission

WBC	9100	/ μ l	main specific IgE antibody tests	normal
Neutrophil	41.9	%	Urinalysis	
Eosinophil	23.7	%	sugar	(-)
Basophil	1	%	protein	(-)
Lymphocyte	30.6	%	blood	(-)
Monocyte	23.7	%		
RBC	550	/ μ l	Stool	
Hb	16.1	g/dl	occult blood	(-)
PLT	32.3	/ μ l	parasites	(-)
C-reactive protein	0.01	mg/dl	ova	(-)
AST	13	IU/dl		
ALT	9	IU/dl		
Total protein	6.6	g/dl		
IgE	111.7	IU/ml		
ESR	2	mm/2hr		

and ascites vanished on computed tomography. Steroid dosage was discontinued after three months with tapering doses. But one month after discontinuing the steroid, abdominal pain and peripheral eosinophilia appeared again. We re-started the oral 20mg/day prednisolone. At the time of this report, the patient had been asymptomatic for five months since the re-start of the steroid (Fig.3).

Discussion

EG was first described by Kaijser¹⁾ in 1937, and several hundred cases have been reported. It presents with very heterogeneous clinical manifestations. Any part of the gastrointestinal tract can be involved. It is mainly found in persons 20–50 years old, but can also be found in children. Both sexes are equally affected. Three criteria of Talley et al.³⁾ are used in the diagnosis of EG: (i) the presence of gastrointestinal symptoms; (ii) biopsies showing eosinophilic infiltration of one or more areas of the gastrointestinal tract or typical radiological findings with a peripheral eosinophilia; and (iii) no evidence of extra-intestinal disease or parasitic disease.

Klein et al.²⁾ have proposed to classify eosinophilic gastroenteritis according to the layer of gastrointestinal tract involved. The clinical presentation depends on the gastrointestinal, division affected and the wall layers infiltrated. Mucosal type, the most common form of presentation, may result in iron deficiency anemia, nausea, vomiting and protein-losing enteropathy. Patients with mucosal involvement and their family members frequently have histories of atopic disease. The muscular layer type generally has obstructive symptoms⁴⁾. Subserosal eosinophilic infiltration may result in the development of ascites. This type is the rarest: 12.5% in the report of Talley et al.³⁾ and 9% in the study by Nishimura et al.⁵⁾. The presence of ascites in EG is also rare. In a review of 220 cases, Naylor⁶⁾ reported ascites in 5% of the cases. Ascites in this disorder typically has an eosinophilic-rich content^{7,8)}. If possible, ascites should be punctured and examined cytologically.

The etiology of this disease is still unknown. There have been previously reported associations with allergy, allergic diathesis, and acute pancreatitis⁹⁾. Nayer⁶⁾ reported a history of food allergy in 52% of cases. However, information regarding eosinophil biology in both health and disease is developing rapidly. Much has been found in recent years regarding the molecular steps involved in eosinophil development and trafficking, with special attention to the

important role of the transcription factor GATA-1, the eosinophil-selective cytokine IL-5 and the eotaxin subfamily of chemokines¹⁰⁾.

Patients with mild symptoms can be managed with expectant observation. With disabling symptoms, steroid therapy is the mainstay of medical treatment and is effective for many cases of GE; the dose can be tapered slowly after a few weeks of therapy. However, the therapy is associated with a high percentage of recurrence, as in our case, as well as side effects. There have been several reports of a steroid-sparing drug. Sodium cromoglycate is a stabilizer of the membrane of the mast cells that has been used in the treatment of food allergy and in malabsorption¹¹⁾. Ketotifen is an H1-class antihistamine that stabilizes mast cells and possibly impairs eosinophil migration to target organs¹²⁾. There are some reports that have coexisting mucosal EG and *H.pylori* infection¹³⁾. It is suggested that *H.pylori* may play a pathogenic role in the development of blood eosinophilic and EG. Kawaguchi et al.¹⁴⁾ reported EG cured with helicobacter pylori eradication. Garrett et al. suggested that anti-IL-5 (mepolizumab) might be safe and effective in lowering eosinophil levels, and have potential steroid-sparing effects in patients with hyper-eosinophilic syndromes¹⁵⁾. Dietary restriction of soy, milk, eggs, wheat and/or gluten, and beef and its benefits remains controversial. Surgical intervention may be required in patients with obstructive complications or refractory disease.

Long term follow-up is required as there are always chances of recurrence and the natural history of this disease remains unclear. Finally, we underscore that the management of EG is to be kept in mind. We can avoid unnecessary surgery with recognizing EG. With increasing awareness of EG, cases can be diagnosed without surgery using clinical suspicion.

References

- 1) Kaijser R. Zur Kenntnis der allergischen Affektion des Verdauungskanal vom Standpunkt des Chirurgen aus. Arch Klin Chir 1937;188:39-64.
- 2) Klein NC, Hargrove RL, Sleisenger MH, Jefferies GH. Eosinophilic gastroenteritis. Medicine 1970;49:299-319.
- 3) Talley NJ, Shorter RG, Phillips SF, Zinsmeister AR. Eosinophilic gastroenteritis: a clinicopathological study of patients with disease of the mucosa, muscle layer, and subserosal tissues. Gut 1990;31:54-58.

- 4) Hümmer-Ehret BH, Rohrschneider WK, Oleszczuk-Raschke K, Darge K, Nutzenadel W, Troger J. Eosinophilic gastroenteritis mimicking idiopathic hypertrophic pyloric stenosis. *Pediatr Radiol* 1998;28:711-713.
- 5) Nishimura H, Oura M, Tomita T. A case of eosinophilic enteritis and reviews of Japanese literature. *Gastroenterol Endosc* 1989;31:2196-2204.
- 6) Naylor AR. Eosinophilic gastroenteritis. *Scott Med J* 1990;35:163-165
- 7) Miyamoto T, Shibata T, Matsuura S, Kagesawa M, Ishizawa Y, Tamiya K. Eosinophilic gastroenteritis with ileus and ascites. *Intern med* 1996;35:779-782.
- 8) Zou HB, Jin-Ming Chen, Qun D. Eosinophilic gastroenteritis with ascites and hepatic dysfunction. *World J Gastroenterol* 2007;13:1303-1305.
- 9) Lyngbaek S, Adamsen S, Aru A, Bergenfeldt M. Recurrent acute pancreatitis due to eosinophilic gastroenteritis. case report and literature review. 2006;JOP 9:211-217.
- 10) Fulkerson PC, Rothenberg ME. Origin, regulation and physiological function of intestinal eosinophils. *Best Pract Res Clin Gastroenterol* 2008;22:411-423.
- 11) Pérez-Millán A, Martín-Lorente JL, López-Morante A, Yuguero L, Saez-Royuela F. Subserosal eosinophilic gastroenteritis treated efficaciously with sodium cromoglycate. *Dig Dis Sci* 1997;42:342-344.
- 12) Freeman HJ. Longstanding eosinophilic gastroenteritis of more than 20 years. *Can J Gastroenterol* 2009; 23:632-634.
- 13) Papadopoulos AA, Tzathas C, Polymeros D, Ladas SD. Symptomatic eosinophilic gastritis cured with *Helicobacter pylori* eradication. *Gut* 2005;54:1822.
- 14) Kawaguchi Y, Mine T, Yasuzaki H, Kusakabe A, Kawana I, Uemura S. Eosinophilic gastroenteritis cured with *Helicobacter pylori* eradication. *J Clin Gastroenterol* 2008;42:1063-1064.
- 15) Garrett JK, Jameson SC, Thomson B, Collins MH, Wagoner LE, Freese DK, et al. Anti-interleukin-5 (mepolizumab) therapy for hypereosinophilic syndromes. *J Allergy Clin Immunol* 2004;113:115-119.

腹水を伴った若年者の好酸球性胃腸炎の1例

渡邊照彦¹⁾, 石神純也¹⁾, 才原哲史²⁾, 夏越祥次¹⁾

¹⁾ 鹿児島大学腫瘍制御学消化器外科, ²⁾ 曾於郡医師会立病院外科

今回、若年者の好酸球性胃腸炎の1例を報告する。症例は13歳の男性である。腹痛、下痢を主訴として15ヶ月前に入院となった。末梢血液検査にて著明な好酸球増多がみられた。腹部CTおよび腹部超音波検査にて広範囲の腸管壁の浮腫と、中等量の腹水を認めた。上部および下部消化管内視鏡はほぼ正常所見を呈し、生検では異常は無かった。感染性疾患、寄生虫感染、自己免疫疾患、hypereosinophilic syndromeは否定され、漿膜下型の好酸球性胃腸炎と診断された。ステロイドを使用し、症状は著明に改善した。好酸球性胃腸炎は比較的稀な疾患で、胃から大腸に至る消化管の全層に好酸球の浸潤を起し得る。本疾患の原因は未だ不明であるが、最近になり分子生物学的な研究も行われつつある。治療はステロイドが中心となる。腹部の愁訴を伴う患者を診察する際は、この疾患の存在を念頭に置くことが重要である。