

Superior Mesenteric Artery Syndrome Associated with Total Situs Inversus

Sumiya ISHIGAMI, Shoji NATSUGOE, Hiroshi KURAHARA, Masataka MATSUMOTO,
Masaki KITAZONO, Hiroyuki SHINCHI, Shin-ichi UENO and Takashi AIKOU

Surgical Oncology, Digestive Surgery, Kagoshima University School of Medicine, Kagoshima, Japan

(Accepted 5 February 2008)

Abstract

A 58-year-old man was admitted to Kagoshima University Hospital after developing acute-onset abdominal distension. He had experienced anorexia and had lost 2 kg over the previous 3 months. An upper GI series and abdominal CT suggested duodenal obstruction with superior mesenteric artery syndrome (SMAS) and total situs inversus (TSI). As obstructive symptoms were refractory to conservative treatment with naso-gastric decompression and positional change, surgical treatment was performed 14 days after his admission. At laparotomy, complete transposition of the abdominal organs was observed. Although malrotation of the jejunum was not identified, a fibrotic stricture of the Treitz ligament was found. The duodenum and jejunum were reconstructed with duodeno-jejunostomy and jejuno-jejunostomy. Symptoms improved after surgery and the patient was discharged after 30 days, with no postoperative complications.

SMA syndrome is very rarely associated with TSI, and to our knowledge, this is the first report in the literature written by English.

Key words: superior mesenteric artery, total situs inversus

Introduction

Superior mesenteric artery syndrome (SMAS) is a rare condition that is commonly caused by extrinsic compression of the third portion of the duodenum, and tends to present with vomiting. Duodenography and abdominal CT are required for confirmation of the diagnosis¹⁾. On the other hand, total situs inversus (TSI) is often asymptomatic in the absence of associated malformation. The overall incidence of this malformation is reported to range from 1/8000 to 1/2500²⁾. TSI has been reported in association with intestinal obstruction due to incomplete mesenteric rotation or other intestinal malrotation³⁾. However, SMAS occurring in TSI that does not involve gastro-intestinal malrotation has not been reported in the English literature.

Case Report

A 58-year-old male was referred and admitted to Kagoshima University Hospital with acute-onset abdominal distension. Over the previous 3 months, the patient had developed anorexia and had lost 2 kg in weight. An upper GI series and abdominal CT suggested duodenal obstruction with SMAS and TSI. Conservative treatment with naso-gastric decompression and fluid resuscitation ameliorated dehydration but failed to improve the obstructive symptoms. Abdominal surgery was therefore performed 14 days after his admission. At laparotomy, TSI was observed. Although the second part of the duodenum was dilated, this appeared to have resulted from fibrous stricture rather than from non-rotation of the small intestine. After mobilization of the duodenum, duodeno-jejunostomy and jejuno-jejunostomy were performed. Postoperatively, gastrointestinal transit

Address for reprint requests: Dr. Sumiya Ishigami M.D.
Surgical Oncology, Digestive Surgery, Kagoshima
University School of Medicine, 8-35-1 Sakuragaoka,

Kagoshima, 890-8520, Japan
Tel: +81-99-275-5361, Fax: +81-99-265-7426
E-mail: Ishiga@m.kufm.kagoshima-u.ac.jp

normalized, no complications were noted and the patient was discharged after 30 days' hospitalization. At present, after 3 years of postoperative follow-up, the patient remains well.

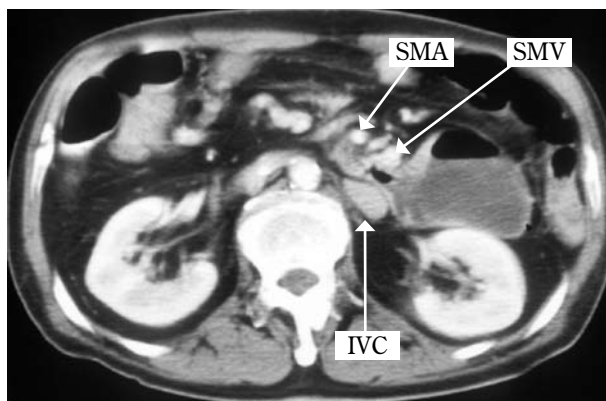


Fig.1. Abdominal CT indicated total situs inversus. Second part of the duodenum was remarkably dilated and narrowed in the aorto-SMA angle, suggesting superior mesenteric artery syndrome. The third portion of duodenum was compressed by sharpness of aorto-SMA angle. SMA: super mesenteric artery, SMV: super mesenteric vein, IVC: inferior vena cava.

Discussion

Adult onset SMAS is well known to be caused by sharpness of aorto-SMA angle, loss of mesenteric and retroperitoneal fat, short ligament of Treitz, and unusually low origin of the SMA. In the current case, the patient exhibited fibrotic stricture of the ligament of Treitz, which was therefore shortened. The literature contains a few reports of TSI associated with malrotation of the intestine, diagnosed in the neonatal period⁹⁾; however, it is considered that the present patient had an asymptomatic anomaly of duodenum.

SMAS is an abnormality that can potentially occur in TSI. However, the most clinically significant complications of TSI are cardiac and gastro-intestinal anomalies and difficulties in diagnosis or treatment. Although the present patient had TSI, no cardiovascular anomalies were present and duodeno-jejunostomy and jejuno-jejunostomy were straightforward to perform. Ylinen⁴⁾ demonstrated duodeno-jejunostomy to have good results in SMAS patients refractory to conservative therapy, a finding that is supported by the present case. Several reports have demonstrated that TSI is associated with various

types of cancer⁹⁾. In Japan, more than 40 patients with TSI are reported to have developed gastric cancer in the last 15 years. Close postoperative follow-up is therefore necessary in order to detect neoplasia. In conclusion, review of the pathogenesis of SMAS is indicated considering the rare occurrence of the present anomaly. However, it would appear that surgical management is the same as that employed for SMAS patients without TSI.

References

- 1) Lippl F, Hannig C, Weiss W, Allescher HD, Classen M, Kurjak M. Superior mesenteric artery syndrome: diagnosis and treatment from the gastroenterologist's view. *J Gastroenterol* 2002; 37: 640–643.
- 2) Douard R, Chevallier JM, Loric S, Cugnenc PH, Delmas V. Total situs inversus: a genetic material bank as a new tool for anatomical research. *Surg Radiol Anat* 2003; 25: 173–174.
- 3) Ruben GD, Templeton JM Jr, Ziegler MM. Situs inversus: the complex inducing neonatal intestinal obstruction. *J Pediatr Surg* 1983; 18: 751–756.
- 4) Ylinen P, Kinnunen J, Hockerstedt K. Superior mesenteric artery syndrome. A follow-up study of 16 operated patients. *J Clin Gastroenterol* 1989; 11: 386–391.
- 5) Kim YI, Tada I, Kawakawa A, Kobayashi M. Double cancer of the liver and stomach with situs inversus totalis—a case report. *Jpn J Surg*. 1989; 19: 756–9.

内臓逆位症を伴った上腸間膜動脈症候群の1例

石神純也, 夏越祥次, 蔵原 弘, 松本正隆,
北薊正樹, 新地洋之, 上野真一, 愛甲 孝

鹿児島大学大学院腫瘍制御学消化器外科

まれな完全内臓逆位をともなった上腸間膜動脈（以下SMA）症候群の1例を経験した。症例は58歳の男性。食欲不振と体重減少を主訴に当院を受診し、腹部CT検査にてSMA症候群による十二指腸閉塞と完全内臓逆位を認めた。胃へ減圧チューブを挿入して保存的加療を行うも奏効せず、手術を行った。上腹部正中切開で開腹した。腹部臓器は逆位であったが、腸管の異常回転は認められなかった。トライツ靭帯の線維性の肥厚と十二指腸の狭窄が見られた。縫合器により胃腸吻合を側側で行い、消化管のバイパスを行った。術後、食物の通過は容易となり、狭窄症状は軽快し、30日目に退院となった。内臓逆位を伴ったSMA症候群の報告はまれであり、これが英文を含めても、はじめての報告であった。