

Evaluation of maxillary central incisors on the noncleft and cleft sides in patients with unilateral cleft lip and palate—Part 1: *Relationship between root length and orthodontic tooth movement*

Aya Maeda-Iino^{a*}; Kanako Marutani^{b*}; Minami Furukawa^b; Shoko Nakagawa^b; Sangho Kwon^b; Toshiro Kibe^c; Masahiro Tezuka^c; Norifumi Nakamura^d; Shouichi Miyawaki^e

ABSTRACT

Objectives: To measure the root lengths of maxillary central incisors (U1) and evaluate the relationship among U1 root length, tooth movement, and type of treatment appliance in patients with unilateral cleft lip and palate over a long-term follow-up period.

Materials and Methods: Occlusal radiographs of 30 patients with unilateral cleft lip and palate, acquired less than 6 months before secondary alveolar bone grafting (SBG, T1) and after edgewise treatment (T2), were measured for U1 root length (R1 and R2, root lengths at T1 and T2, respectively). Frontal and lateral cephalometric radiographs acquired at eruption of U1 (T0), T1, and T2 were evaluated to determine the inclination and position of U1.

Results: The average values of R1 and R2 on the cleft side were significantly lower than those on the noncleft side. Frontal cephalometric analysis revealed that the horizontal distance of the root apex from the median vertical line at T0 on the cleft side was significantly smaller than that on the noncleft side and was correlated with short U1 root length on the cleft side. On the other hand, R1 in patients treated with maxillary protraction appliances between T0 and T1 was significantly shorter than that in patients without maxillary protraction appliances. However, none of the changes in cephalometric measurements were correlated with root length.

Conclusions: In patients with unilateral cleft lip and palate, the short root length of cleft-adjacent central incisors might be associated with the horizontal position of the root apex. In addition, orthodontic treatment with a maxillary protraction appliance before secondary alveolar bone grafting might be associated with short U1 root length. (*Angle Orthod.* 2017;87:855–862.)

KEY WORDS: Root lengths of maxillary central incisors; UCLP; orthodontic tooth movement; Long-term follow-up

INTRODUCTION

In patients with cleft lip and palate (CLP), some teeth, especially maxillary incisors, often develop short roots.¹ Those short roots might complicate treatment planning in orthodontic management or

and Dentofacial Orthopedics, Graduate School of Medical and Dental Sciences, Kagoshima University, Kagoshima, Japan.

Corresponding author: Dr Shouichi Miyawaki, Field of Developmental Medicine, Health Research Course, Graduate School of Medical and Dental Sciences, Department of Orthodontics and Dentofacial Orthopedics, 8-35-1 Sakuragaoka, Kagoshima, Kagoshima 890-8544 Japan (e-mail: miyawaki@dent.kagoshima-u.ac.jp)

Accepted: July 2017. Submitted: March 2017.

Published Online: September 14 2017

© 2017 by The EH Angle Education and Research Foundation, Inc.

* The first two authors contributed equally to this study.

^a Assistant Professor, Field of Developmental Medicine, Health Research Course, Department of Orthodontics and Dentofacial Orthopedics, Graduate School of Medical and Dental Sciences, Kagoshima University, Kagoshima, Japan.

^b Postgraduate Student, Field of Developmental Medicine, Health Research Course, Department of Orthodontics and Dentofacial Orthopedics, Graduate School of Medical and Dental Sciences, Kagoshima University, Kagoshima, Japan.

^c Assistant Professor, Field of Oral and Maxillofacial Rehabilitation, Advanced Therapeutics Course, Department of Oral and Maxillofacial Surgery, Graduate School of Medical and Dental Sciences, Kagoshima University, Kagoshima, Japan.

^d Professor and Department Chair, Field of Oral and Maxillofacial Rehabilitation, Advanced Therapeutics Course, Department of Oral and Maxillofacial Surgery, Graduate School of Medical and Dental Sciences, Kagoshima University, Kagoshima, Japan.

^e Professor and Department Chair, Field of Developmental Medicine, Health Research Course, Department of Orthodontics

prosthodontics, which is a major concern for orthodontists.

Apart from short roots, several studies have found that patients with CLP also exhibit delayed root development relative to normal reference populations.¹⁻³ The roots of the maxillary incisors (U1) in patients with CLP are significantly shorter than those in patients without CLP,¹ which suggests that genetic factors might play a role in development of short-rooted teeth. On the other hand, it has been reported that root development in cleft-adjacent lateral incisors is delayed relative to that on the noncleft side^{4,5} and that root resorption on the cleft side is higher than that on the noncleft side.⁴ Surgical cleft repair results in fibrosis and reduced blood supply, causing damage to developing tooth buds in the cleft area.⁶ Mechanisms controlling dental development are highly influenced by the same etiological factors that influence cleft formation.⁷ However, previous studies have not evaluated root development at the same treatment stage or in patients of similar age. Therefore, the causes of shortness of dental roots and root resorption in patients with CLP have yet to be demonstrated. Moreover, the relationship between root length and the position or movement of teeth upon orthodontic treatment is yet unclear.

This study aimed to (1) evaluate root length and tooth position of U1 on the noncleft and cleft sides in patients with unilateral CLP (UCLP), (2) compare cephalometric measurements on the noncleft and cleft sides, and (3) evaluate the relationship between root length and tooth position following orthodontic treatment using different treatment appliances.

MATERIALS AND METHODS

This study was approved by the Kagoshima University Ethics Committee (#519, 589, 661).

Patients

Among consecutive patients with CLP treated at the Department of Orthodontics, Kagoshima University Medical and Dental Hospital, Kagoshima, Japan, between 1983 and 2015, 30 patients who met the inclusion and exclusion criteria were enrolled (Table 1). The inclusion criteria were the presence of complete UCLP, orthodontic and surgical treatment for UCLP at the hospital, and similar orthodontic treatment in the cleft area in accordance with the following protocol (N = 66): (1) alignment of the cleft-adjacent U1 by lingual inclination or rotation, being careful to avoid movement of the roots into the cleft area, and expansion of the maxillary arch before secondary alveolar bone grafting (SBG) in cases where the maxillary dental arch displayed constriction of the minor segment; (2) SBG during the mixed dentition; (3) initiation of orthodontic

Table 1. Sex and Age Distribution of Patients at Each Evaluation Period and Mean Observation Period

Variable	n/n or Mean \pm SD ^a
Sex, male/female, N)	16/14
Age at T0 ^a (y)	7.80 \pm 0.87
at T1 (y)	10.50 \pm 1.51
at T2 (y)	16.49 \pm 1.70
Observation period (y)	8.70 \pm 1.78

^a T0 indicates at eruption of central incisors; T1, at less than 6 months prior to secondary bone grafting; T2, after edgewise treatment. ^bSD, standard deviation.

treatment, including edgewise treatment in the graft area, with treatment for cleft-adjacent teeth at 3 months post-SBG in cases requiring tooth movement into the graft area; and (4) edgewise treatment of the maxillary and mandibular permanent teeth. The exclusion criteria were treatment involving maxillary orthognathic surgery, unavailability of radiographs required for this study, the presence of cleft-adjacent lateral incisors or cleft-adjacent supernumerary teeth in the major segment, root apex of U1 not closed before SBG (Nolla developmental stages⁸ < 9), congenitally missing U1, and crown and root length not measurable (eg, when the root apex was not imaged or the crown was fitted with a large dental prostheses; N = 36).

Measurement of Root Length

Occlusal radiographs of the maxillary anterior occlusion, including the cleft area, were acquired by radiologists using a standard radiologic technique (long-cone technique, with root direction perpendicular to the palatine midline). Images acquired less than 6 months before SBG (T1) and after edgewise treatment (T2) were evaluated. The outlines of U1 from occlusal radiographs were traced on acetate sheets. Crown height and root length were defined as shown in Figure 1⁹ and measured using digital calipers. Correction factors (CF) were calculated on the basis of crown heights at T1 and T2 (C1 and C2, respectively) as follows: CF = C2/C1. Although root length at T2 (R2) was determined in accordance with the original measurement, that at T1 (R1) was calculated as follows: Original measurement root length at T1 \times CF.

To validate the accuracy of occlusal radiograph measurements, the method errors (ME) for occlusal radiograph measurements were compared with those of periapical radiograph measurements of U1 in 15 patients who had undergone imaging by both methods during the same period. In addition, inter- and intra-examiner (AM and KM) reproducibility and reliability of root length measurements were assessed on the basis of ME. U1 in these occlusal and periapical radiographs were retraced after a minimum interval of 2 months. The ME for dental root length was calculated using the

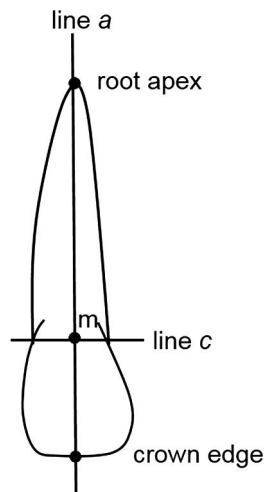


Figure 1. Measurement of crown height and root length. Line a, longitudinal axis along the root canal from the root apex to the incisal edge; line c, line drawn through the mesial and distal sides of the cemento-enamel junction; and point m, intersection of lines a and c. Crown height and root length were measured along line a from the incisal edge and root apex, respectively, to point m.

following Dahlberg formula¹⁰:

$$ME = \sqrt{\sum(d^2/2n)},$$

where d is the intra- and interexaminer difference in root length, and n is the number of evaluated teeth. The MEs for the inter- and intraexaminer reliability of root length measurements were 0.25 and 0.59 for occlusal radiographs and 0.31 and 0.45 for periapical radiographs, respectively. There were no significant differences in original root-length measurements between occlusal and periapical radiographs (matched paired t-test).

Evaluation of Frontal and Lateral Cephalometric Radiographs

Cephalometric radiographs of all patients acquired at the eruption of U1 (T0), T1, and T2 were evaluated for dentofacial morphological characteristics. The radio-

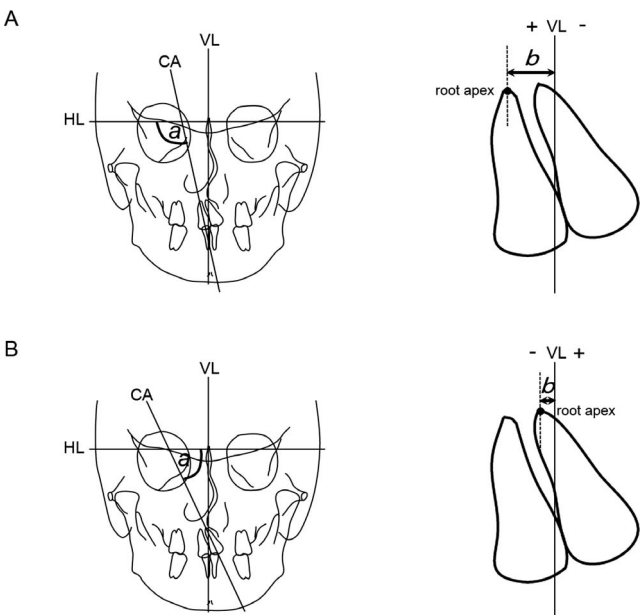


Figure 2. Frontal cephalometric analysis. A, noncleft side; B, cleft side; a, long-axis angle (°); b, U1-root-VL distance (mm). U1 indicates maxillary incisor; VL, vertical line; HL, horizontal line; CA, central incisal axis.

graphs were traced by the authors, and the angles were determined using WinCeph 9.0 software (CompuDent, Koblenz, Germany). Distances were measured using digital calipers.

Figure 2 presents the frontal cephalometric variables evaluated. Two reference lines, a horizontal line (HL) connecting the right and left latero-orbitale points and a vertical line (VL) through the center of the crista galli perpendicular to HL, were traced for the vertical and horizontal measurements. The internal angle between HL and central incisal axis CA was defined as the U1-axis angle (a, Figure 2). The horizontal distance between the VL and the root apex of U1 was defined as the U1-root-VL distance (b, Figure 2).

The inclination and position of U1 were determined by lateral cephalometric analysis (Figure 3). Axial proclination of U1 to the anterior cranial base was

Table 2. Comparison of Central Incisor Root Length Between the Cleft and Noncleft Sides and Results of Fixed-Effects Analysis

Measurement	Noncleft Side, n = 30	Cleft Side, n = 30	P Value ^a	Fixed Effects					
				Noncleft or Cleft		Period, T1 and T2 ^b		Noncleft or Cleft × Period, T1 and T2	
	Adjusted Mean	Adjusted Mean		F Value	P Value ^a	F Value	P Value ^a	F Value	P Value ^a
Root length (mm)									
T1	14.46	12.81	.003*	15.628	<.001***	10.747	<.001***	0.075	NS
T2	13.07	11.63	.010*						
P value, T1 vs T2	.013*	.036*							

^a P values derived using a generalized linear model with each patient being considered as the covariate. Indicates significance at P < .05 after Bonferroni adjustment for multiple comparisons. NS indicates not significant.
^b T1, less than 6 months prior to secondary bone grafting; T2, after edgewise treatment.
*P < .05; ***P < .001.

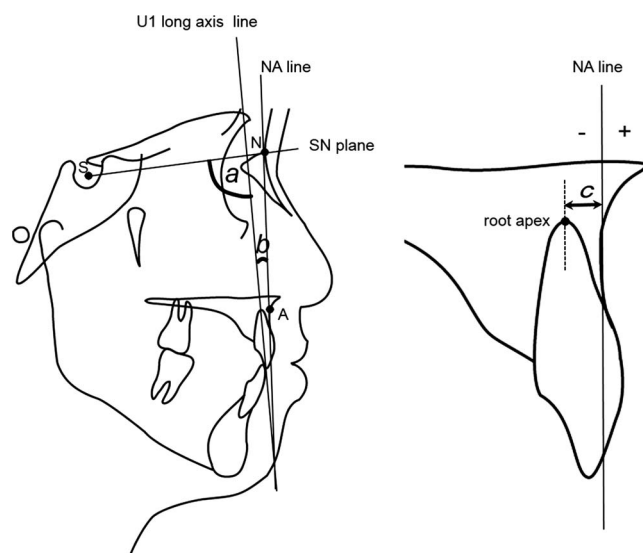


Figure 3. Lateral cephalometric analysis. a, U1–SN angle ($^{\circ}$); b, U1–NA angle ($^{\circ}$); c, U1–root–NA distance (mm). U1 indicates maxillary incisor; SN, sella–nasion; NA, nasion.

determined by the angle between the long axis of U1 (U1 long-axis line) and the sella–nasion (SN) plane (U1–SN angle; a, Figure 3). According to the Steiner analysis, the relationship between U1 and nasion (NA) line (line from NA to point A) indicates the relative protrusion of teeth. The distance between the U1 root apex and the NA line (U1–root–NA distance; distance c, Figure 3) and the angle between the long axis of U1 and the NA line (U1–NA angle; b, Figure 3) were determined.

For the assessment of intraexaminer reproducibility and reliability of the measurements, 30 each of randomly selected frontal and lateral cephalometric radiographs (T0, T1, and T2, 10 each) were retraced after a minimum interval of 2 months. The evaluation of discrepancies in measurements between the original and retraced radiographs (matched paired *t*-test) revealed no statistically significant differences.

Evaluation of Orthodontic Appliances Used

Most of the patients received treatment with some orthodontic appliance such as a maxillary protraction appliance (MPA), rapid maxillary expansion, or quad helix before edgewise treatment. Data regarding the type of appliance were obtained from medical records. It was also investigated whether each of the patients did or did not receive any of the three types of appliances.

Statistical Analysis

Measurements (R1, R2, and cephalometric parameters) recorded on the noncleft and cleft sides at each

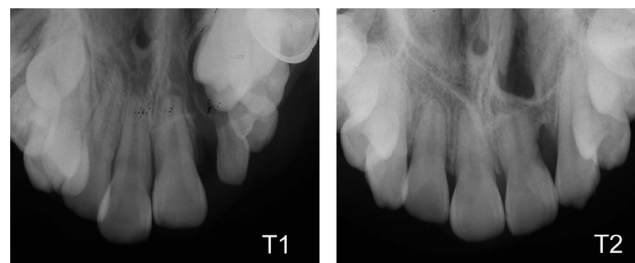


Figure 4. Occlusal radiographs showing central incisors before secondary alveolar bone grafting (T1) and after edgewise treatment (T2) in a patient with unilateral cleft lip and palate on the left side.

time point were compared using generalized linear models adjusted for measurement period and individual (each patient) effects. Statistical significance was set at $P < .05$ after Bonferroni adjustment for multiple comparisons. The linear mixed model approach for longitudinal comparison across time points and varying data hierarchies was used (highest-level hierarchy: patients or treatment appliances used; next level down: cleft/noncleft side or root length and cephalometric measurements on each side). The probability of significance was calculated for each comparison. Statistical tests were performed using SPSS version 24.0 for Windows (IBM, Armonk, N.Y.).

RESULTS

Both R1 and R2 on the cleft side were significantly shorter than those on the noncleft side ($P = .003$ and $.010$, respectively, Table 2). Figure 4 presents occlusal radiographs of a typical case of UCLP. On both sides, R2 was significantly shorter than R1. However, there was no statistically significant change in the root length measurement over time on the noncleft side ($P > 0.05$, Table 2), which indicated that there was no significant difference in root resorption from T1 to T2 between the two sides. Therefore, the next step investigated the reason why R1 on the cleft side was shorter than that on the noncleft side.

Almost all frontal and lateral cephalometric measurements on the cleft side differed significantly from those on the noncleft side at each period (Table 3). There was no statistically significant change in cephalometric measurements over time on the noncleft side (Table 4), which indicated that there was no significant difference in tooth movement from T0 and T1 between the two sides. However, the statistically significant U1–root–VL distance at T0 \times noncleft for the R1 indicated a differential tooth position in cephalometric measurements according to the side (noncleft or cleft side; $P = 0.044$; Table 5).

The effects of orthodontic treatment appliances on R1 were evaluated. The MPA significantly affected the R1; however, other appliances and each appliance \times

Table 3. Comparison of Cephalometric Measurements Between the Cleft and Noncleft Sides and Among Different Periods

Measurements ^a	Noncleft Side, n = 30		Cleft Side, n = 30	P Value ^b
	Adjusted Mean	Adjusted Mean		
Frontal cephalometric analysis				
U1-axis angle (°)				
T0	90.77	72.05		<.001***
T1	94.48	72.60		<.001***
T2	94.27	81.66		<.001***
P value, T0 vs T1	NS	NS		
P value, T1 vs T2	NS	<.001***		
U1-root-VL distance (mm)				
T0	5.74	-0.63		<.001***
T1	5.61	-0.08		<.001***
T2	4.84	2.16		<.001***
P value, T0 vs T1	NS	NS		
P value, T1 vs T2	NS	<.001***		
Lateral cephalometric analysis				
U1-SN angle (°)				
T0	91.11	85.70		.013*
T1	94.51	90.30		NS
T2	101.63	101.43		NS
P value, T0 vs T1	NS	NS		
P value, T1 vs T2	.003**	<.001***		
U1-NA angle (°)				
T0	14.02	7.95		.004**
T1	17.39	13.19		.045*
T2	26.83	25.62		NS
P value, T0 vs T1	NS	.035*		
P value, T1 vs T2	<.001***	<.001***		
U1-root-NA distance (mm)				
T0	-7.10	-5.01		<.001***
T1	-5.57	-4.40		.007**
T2	-5.57	-4.47		.007**
P value, T0 vs T1	.007**	NS		
P value, T1 vs T2	NS	NS		

^a U1 indicates central incisor; T0, at eruption of U1; T1, less than 6 months prior to secondary bone grafting; T2, after edgewise treatment; VL, vertical line; SN, sella-nasion; NA, nasion-point A.

^b P values derived using a generalized linear model with each patient being considered as the covariate. Indicates significance at $P < .05$ after Bonferroni adjustment for multiple comparisons. NS indicates not significant.

* $P < .05$; ** $P < .01$; *** $P < .001$.

Table 5. Relationship Between Cephalometric Measurements on the Noncleft or Cleft Side at T0 and Root Length at T1

Fixed Effects ^a	Root Length at T1 (R1)	
	F Value	P Value ^b
Noncleft or cleft side	0.279	NS
U1-axis angle at T0 (°)	0.047	NS
U1-root-VL distance at T0 (mm)	1.299	NS
U1-SN angle at T0 (°)	0.045	NS
U1-NA angle at T0 (°)	0.172	NS
U1-root-NA distance at T0 (mm)	0.011	NS
U1-axis angle at T0 × noncleft side	0.810	NS
U1-root-VL distance at T0 × noncleft side	4.234	.044*
U1-SN angle at T0 × noncleft side	1.199	NS
U1-NA angle at T0 × noncleft side	3.879	NS
U1-root-NA distance at T0 × noncleft side	1.423	NS

^a U1 indicates central incisor; T0, at eruption of U1; T1, less than 6 months prior to secondary bone grafting; VL, vertical line; SN, sella-nasion; NA, nasion-point A.

^b P values derived using the mixed model approach. NS indicates not significant.

^c The estimated value was 0.742 (standard error, 0.36) when the U1-root-VL distance on the noncleft side was compared with that on the cleft side.

* $P < .05$.

noncleft did not (Table 6). There was no statistically significant change in cephalometric measurements over time on the patients treated without MPA (Table 7), which indicated that there was no significant difference in tooth movement from T0 to T1 between with or without MPA. Patients treated with MPA exhibited significantly shorter R1 in all U1 on the noncleft side than did patients treated without MPA ($P = .013$ and $.035$, respectively, Table 8); there was no significant difference in R1 on the cleft side between the two groups of patients. In patients treated without MPA, R1 on the cleft side was significantly shorter than that on the noncleft side ($P = .005$, Table 8). In contrast, in patients treated with MPA, there was no significant difference in R1 between the two sides (Table 8).

Table 4. Results of Fixed-Effects Analysis of Cephalometric Measurements

Measurements ^a	Fixed Effects					
	Noncleft or Cleft		Period, T0 and T1		Noncleft or Cleft × Period, T0 and T1	
	F Value	P Value ^b	F Value	P Value ^b	F Value	P Value ^b
Frontal cephalometric measurements						
U1-axis angle (°)	280.181	<.001***	3.091	NS	0.196	NS
U1-root-VL distance (mm)	430.318	<.001***	0.498	NS	1.374	NS
Lateral cephalometric measurements						
U1-SN angle (°)	13.763	<.001***	9.519	.003**	0.218	NS
U1-NA angle (°)	17.168	<.001***	12.034	.001**	0.570	NS
U1-root-NA distance (mm)	29.885	<.001***	11.206	.001**	1.800	NS

^a U1 indicates central incisor; T0, at eruption of U1; T1, less than 6 months prior to secondary bone grafting; VL, vertical line; SN, sella-nasion; NA, nasion-point A.

^b P values derived using the mixed model approach. NS indicates not significant.

** $P < .01$; *** $P < .001$.

Table 6. Relationship Between Treatment Appliances on the Noncleft or Cleft Side and Root Length at T1^a

Fixed Effects	Root Length at T1 (R1)	
	F Value	P Value ^b
Treated with		
MPA, N = 12	5.90	.021*
QH, N = 22	1.30	NS
RME, N = 7	1.23	NS
Treatment with MPH on the noncleft side ^c	2.63	NS
Treatment with QH on the noncleft side ^c	1.37	NS
Treatment with RME on the noncleft side ^c	0.10	NS

^a T1 indicates less than 6 months prior to secondary bone grafting; MPA, maxillary protraction appliance; QH, quad helix; RME, rapid maxillary expansion.

^b P values derived using the mixed model approach. NS indicates not significant.

^c Both sides were nested within each treatment appliance.

*P < .05.

DISCUSSION

Computed tomography is the most reliable method for measurement of actual dental root length.¹¹ However, it was not possible to employ this method in this retrospective study. Previous studies have routinely used periapical radiographs for measurement of root length.^{12,13} The present study employed occlusal radiographs for measurement of U1 root length because there were only a few periapical radiographs available that included U1 on both the noncleft and cleft sides. However, there were no significant differences in original root length or ME between occlusal radiographs acquired after edgewise treatment and periapical radiographs of U1 acquired during the same period. Therefore, root length measurement using occlusal radiographs acquired after edgewise treatment was judged to be an acceptable method. An issue encountered during measurement of U1 root length was that anteroposterior inclinations of U1 on the noncleft side at T1 were significantly different from

those on the cleft side, although the corresponding measurements at T2 on both sides were comparable; this discrepancy was rectified by applying CFs calculated in accordance with crown heights at T1 and T2. We believe that the methods used to evaluate U1 root length on the noncleft and cleft sides using occlusal radiographs were acceptable.

In the present study, cleft-adjacent U1 roots were shorter than non-cleft-adjacent U1 roots at T1 (just before SBG). Previous studies have reported asymmetric tooth formation patterns in patients with unilateral CLP.^{4,5} One of the etiological factors for delayed tooth formation in the maxillary cleft is the lack of space for tooth formation in the cleft area^{14,15} and growth attenuation due to inadequate nutrition.⁶ Upon frontal cephalometric analysis, the U1-root-VL distance at T0 on the cleft side was found to be lower than that on the noncleft side; this variable was statistically correlated with root length at T1. During treatment, care was taken to avoid movement of roots into the cleft area before SBG. Consequently, the root-apex position on the cleft side had not changed significantly between T0 and T1. This suggests that cleft-adjacent U1 with the root-apex position shifted to the noncleft side at T0 might have had short roots because of a lack of space for development on the cleft side.

At T2, the roots of cleft-adjacent U1 were shorter than those of U1 on the noncleft side, similar to the trend at T1. However, there was no significant difference in the change in root length from T1 to T2 between the two sides. The cleft and noncleft sides exhibited comparable root resorption in U1 between T1 and T2. Short dental root length on the cleft side after edgewise treatment (R2) might be correlated with root length before SBG (R1).

Root resorption between T0 and T1 could not be evaluated because the root apices at T0 had not closed yet and, consequently, it was not possible to measure the root length. However, most patients with

Table 7. Results of Fixed-Effects Analysis of Cephalometric Measurements in Patients Without MPA

Measurements ^a	Fixed Effects					
	Without MPA		Period, T0 and T1		Without MPA × Period, T0 and T1	
	F Value	P Value ^b	F Value	P Value ^b	F Value	P Value ^b
Frontal cephalometric measurements						
U1-axis angle (°)	0.123	NS	2.427	NS	0.218	NS
U1-root-VL distance (mm)	1.979	NS	0.286	NS	0.009	NS
Lateral cephalometric measurements						
U1-SN angle (°)	4.656	.039*	8.387	.005**	0.301	NS
U1-NA angle (°)	3.918	NS	10.809	.001**	0.173	NS
U1-root-NA distance (mm)	4.441	.046*	11.506	.001**	0.586	NS

^a U1 indicates central incisor; T0, at eruption of U1; T1, less than 6 months prior to secondary bone grafting; MPA, maxillary protraction appliance; VL, vertical line; SN, sella-nasion; NA, nasion-point A.

^b P values derived using the mixed model approach. NS indicates not significant.

*P < .05; **P < .01.

Table 8. Comparison of U1 Root Length Between Patients and Sides Treated With and Without MPA^a

Measurement	Without MPA, N = 18				With MPA, N = 12				Without vs With MPA		
	Adjusted Mean			P Value ^b	Adjusted Mean			P Value ^b	P Value ^b		
	All Teeth, n = 36 U1s	Noncleft Side	Cleft Side		All Teeth, n = 24 U1s	Noncleft Side	Cleft Side		All Teeth	Noncleft Side	Cleft Side
Root length at T1 (mm)	14.27	15.23	13.03	.005**	12.75	13.31	12.47	NS	.013*	.035*	NS

^a U1 indicates central incisor; T1, less than 6 months prior to secondary bone grafting; MPA, maxillary protraction appliance.

^b P values derived using a generalized linear model with each patient being considered as the covariate. Indicates significance at $P < .05$ after Bonferroni adjustment for multiple comparisons. NS indicates not significant.

* $P < .05$; ** $P < .01$.

UCLP in the present study had received treatment with orthodontic appliances between T0 and T1. Root length in patients treated with MPA was significantly shorter than that in patients treated without MPA, although there were no significant differences in changes observed in frontal and lateral cephalometric measurements between the two groups. Some studies have reported that external apical root resorption is associated with the type of loading force used.^{16–18} An orthodontic force of approximately 350 g per side was applied with the MPA, with part of this force transmitted as intermittent force to the maxillary anterior teeth through oral appliances such as a lingual arch. Intermittent orthodontic force has been shown in some studies to have caused less root resorption than continuous force of the same magnitude.^{16,17} On the other hand, in another study, force exerted by J-hook headgear (force applied continuously at night and then completely released during the day) caused greater root resorption than the force applied by tightening a ligature tied from a miniscrew to cause intrusion.¹⁸ The authors of that study suggested that intermittent orthodontic forces such as those exerted by J-hook headgear might cause “jiggling,” which is a known risk factor for external apical root resorption. Recently, a study in rats suggested that jiggling might be a risk factor for root resorption and that it might induce root resorption through production of inflammatory cytokines during orthodontic tooth movement.¹⁹ Jiggling due to the MPA in this study might have caused root resorption or prevented root formation, resulting in short dental roots before SBG. Therefore, treatment with MPA should be started at an early stage, before the eruption of maxillary permanent U1, to decrease the treatment period with MPA after U1 eruption. In addition, maxillary protraction with skeletal anchorage should be considered during the mixed dentition period.

In patients with UCLP, the root lengths of U1 were found to be comparatively short on the cleft side and in teeth treated with MPA. The implications of these findings should be reflected in the treatment plan for UCLP patients.

CONCLUSIONS

- Central incisor roots on the cleft side were shorter than those on the noncleft side both before SBG and after edgewise treatment.
- At eruption and before SBG, cleft-adjacent U1 exhibited a greater shift of the root apex toward the noncleft side than did non-cleft-adjacent U1. This parameter was correlated with root length.
- Root length just before SBG in patients who received treatment with MPA was significantly shorter than that in patients who received treatment without MPA. Thus, orthodontic force exerted by the MPA might result in short dental roots.

ACKNOWLEDGMENTS

This study was supported by grants-in-aid for scientific research (16K11791) from the Japan Society for the Promotion of Science. We are grateful for the assistance of the clinical staff of Kagoshima Hospital. We thank Dr Koji Ataka and Dr Suguru Kawazu, Kagoshima University, for their help with the statistical analyses.

REFERENCES

1. Al-Jamal GA, Hazza'a AM, Rawashdeh MA. Crown-root ratio of permanent teeth in cleft lip and palate patients. *Angle Orthod*. 2010;80:1122–1128.
2. Brouwers HJ, Kuijpers-Jagtman AM. Development of permanent tooth length in patients with unilateral cleft lip and palate. *Am J Orthod Dentofacial Orthop*. 1991;99:543–549.
3. Hazza'a AM, Rawashdeh MA, Al-Jamal G, Al-Nimri KS. Dental development in children with cleft lip and palate: a comparison between unilateral and bilateral clefts. *Eur J Paediatr Dent*. 2009;10:90–94.
4. Ribeiro LL, das Neves LT, Costa B, Gomide MR. Dental development of permanent lateral incisor in complete unilateral cleft lip and palate. *Cleft Palate Craniofac J*. 2002;39:193–196.
5. Solis A, Figueroa AA, Cohen M, Polley JW, Evans CA. Maxillary dental development in complete unilateral alveolar clefts. *Cleft Palate Craniofac J*. 1998;35:320–328.
6. Ranta R. A review of tooth formation in children with cleft lip/palate. *Am J Orthod Dentofacial Orthop*. 1986;90:11–18.
7. Demirjian A, Goldstein H, Tanner JM. A new system of dental age assessment. *Hum Biol*. 1973;45:211–227.

8. Nolla C. The development of the permanent teeth. *J Dent Child*. 1960;27:254–266.
9. Fontana ML, de Souza CM, Bernardino JF, et al. Association analysis of clinical aspects and vitamin D receptor gene polymorphism with external apical root resorption in orthodontic patients. *Am J Orthod Dentofacial Orthop*. 2012;142:339–347.
10. Dahlberg G. *Statistical Methods for Medical and Biological Students*. London: Allen and Unwin; 1940; 122–132.
11. Lund H, Gröndahl K, Gröndahl HG. Cone beam computed tomography for assessment of root length and marginal bone level during orthodontic treatment. *Angle Orthod*. 2010;80:466–473.
12. Becker A, Chaushu S. Long-term follow-up of severely resorbed maxillary incisors after resolution of an etiologically associated impacted canine. *Am J Orthod Dentofacial Orthop*. 2005;127:650–654.
13. Levander E, Malmgren O. Long-term follow-up of maxillary incisors with severe apical root resorption. *Eur J Orthod*. 2000;22:85–92.
14. Eerens K, Vlietinck R, Heidbüchel K, et al. Hypodontia and tooth formation in groups of children with cleft, siblings without cleft, and nonrelated controls. *Cleft Palate Craniofac J*. 2001;38:374–378.
15. Peterka M, Tvrdk M, Müllerová Z. Tooth eruption in patients with cleft lip and palate. *Acta Chir Plast*. 1993;35:154–158.
16. Acar A, Canyürek U, Kocaaga M, Erverdi N. Continuous vs. discontinuous force application and root resorption. *Angle Orthod*. 1999;69:159–163.
17. Ballard DJ, Jones AS, Petocz P, Darendeliler MA. Physical properties of root cementum: part 11. Continuous vs intermittent controlled orthodontic forces on root resorption. A microcomputed-tomography study. *Am J Orthod Dentofacial Orthop*. 2009;136:8.e1–e8.
18. Deguchi T, Murakami T, Kuroda S, Yabuuchi T, Kamioka H, Takano-Yamamoto T. Comparison of the intrusion effects on the maxillary incisors between implant anchorage and J-hook headgear. *Am J Orthod Dentofacial Orthop*. 2008;133:654–660.
19. Hikida T, Yamaguchi M, Shimizu M, Kikuta J, Yoshino T, Kasai K. Comparisons of orthodontic root resorption under heavy and jiggling reciprocating forces during experimental tooth movement in a rat model. *Korean J Orthod*. 2016;46:228–241.