

PATHOGENESIS AND PREVENTION OF DYSBARIC OSTEONECROSIS

Mahito KAWASHIMA, Hiroaki TAMURA, Yoshihiro NORO,
Katsuhiro TAKAO, Motoo KITANO, Charles E. LEHNER,
Yasushi TAYA, Yoshihiro MANO and Teruhiko TSUNOSUE

Abstract

Japanese diving fishermen are known to have a high prevalence of dysbaric osteonecrosis. Their typical dive practices are characterized by long exposure to high pressure and by repetitive diving.

The etiology of dysbaric osteonecrosis still remains controversial. Because the development of dysbaric osteonecrosis may occur silently, the diver may be unaware of the actual ischemic event. Moreover, key etiologic evidence is often lost before the diver is examined.

The early stage of dysbaric osteonecrosis was evaluated in four autopsy cases of divers who died of acute decompression sickness. Hypercoagulability of blood was present in these cases.

Hypercoagulability of blood has also been observed in experimental rats after decompression.

Dysbaric osteonecrosis has been experimentally induced in six sheep at the University of Wisconsin-Madison. These findings are reviewed by comparing dysbaric osteonecrosis in both divers and experimental animals.

In conclusion, a bone compartment syndrome and hypercoagulability appear to be pathogenic factors in dysbaric osteonecrosis.

Key Words : Dysbaric osteonecrosis, Pathogenesis, Bone compartment syndrome, Hypercoagulability, Decompression sickness, Bends

Introduction

The first case of dysbaric osteonecrosis in divers was reported by Grutzmacher in 1941. The prevalence of dysbaric osteonecrosis in Japanese diving fishermen is the highest. In our recent surveys of the Kyushu area, radiological investigation revealed 467 cases (51.6%) osteonecrosis among 905 divers. As we already reported to the past meetings of the United States-Japan Cooperative Program in Natural Resources (UJNR), a characteristic of their diving profile is prolonged hyperbaric exposure and a rapid decompression.

As Elliot and Kindwall (1982) described, prolonged hyperbaric exposure and rapid decompression can provoke a high incidence of limb bends. As we already reported, there appears to be a strong association between limb bends and dysbaric osteonecrosis.

The University of Wisconsin findings of bone necrosis in sheep long bones after hyperbaric exposure provides the basis for a proposed etiological and pathogenic model of dysbaric osteonecrosis.

Our hematological experiments in rats and autopsies in four divers also provides a basis

for an etiological and pathogenic model of dysbaric osteonecrosis.

Histopathology of Early Stage Osteonecrosis

This investigation was based on the histopathological examination of femoral heads taken from four divers who died of decompression sickness.

Case 1 presented the most acute clinical course, with fatal chokes. Multiple air bubbles were found in the femoral sinusoids. A characteristic finding was platelet aggregation in the vicinity of the femoral bubbles (Fig. 1).

The clinical course of case 2 was also acute with chokes and spinal cord paralysis. Fat emboli were seen in the lung vessels (Fig. 2). Air bubbles, platelet aggregation, and an accu-

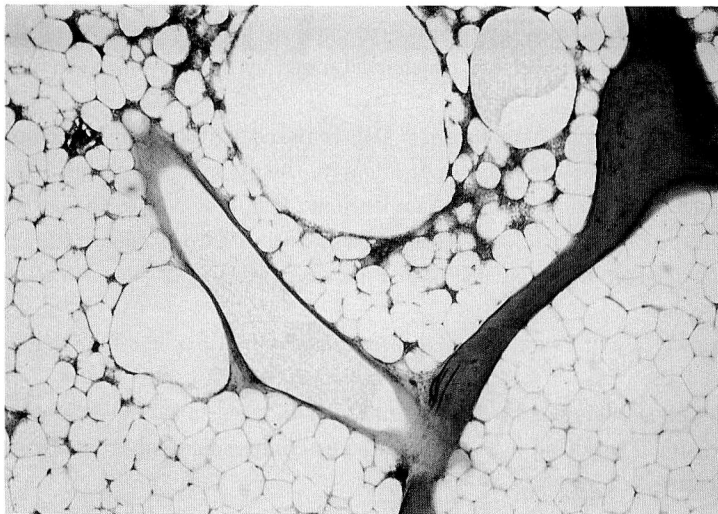


Fig. 1. Case 1: Multiple air bubbles in the femoral sinusoids. Platelet aggregation is seen in the vicinity of the bubbles. x50.

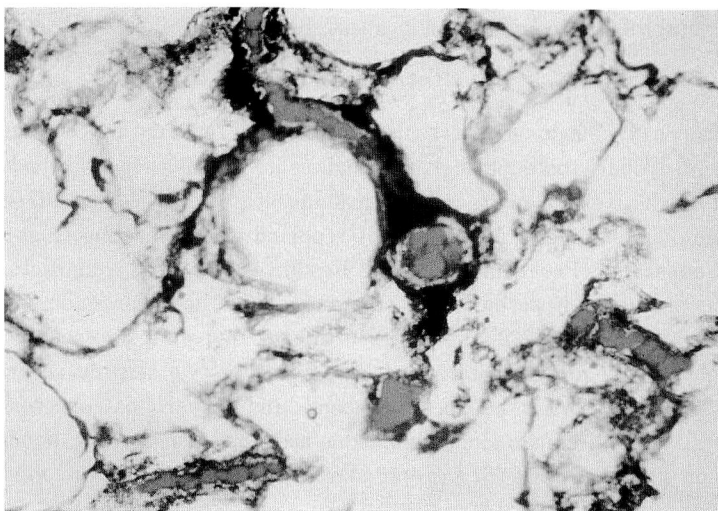


Fig. 2. Case 2: Fat emboli in the lung vessels. x50.

mulation of fat was seen in the dilated sinusoids (Fig. 3).

The diver of case 3 died 5 days after the onset of spinal cord paralysis. An extensive necrosis was noted around the dilated sinusoids. Platelet aggregation and thrombosis were seen in the sinusoids (Fig. 4).

The diver of case 4 died 14 days after the onset of spinal cord paralysis. Slight hemorrhage, migration of phagocytes, and fibrosis were found around the femoral sinusoids (Fig. 5).

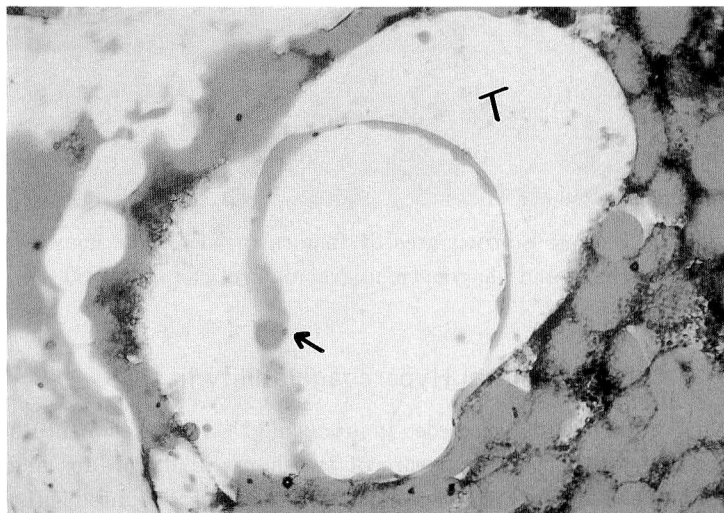


Fig. 3. Case 2: Dilated sinusoid in the femoral head. Accumulation of fat (arrows) and aggregation of platelets (T) are noted in the vicinity of air bubbles. Oil red O, x50.

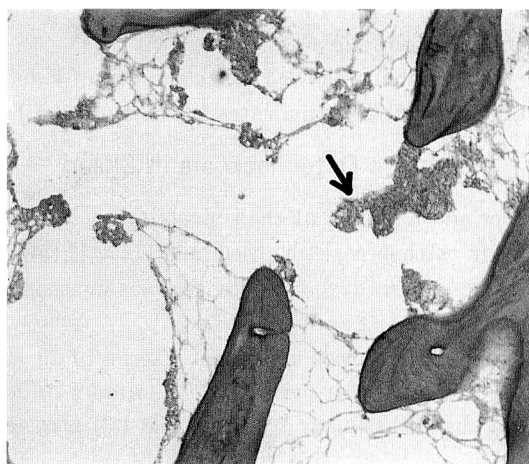


Fig. 4. Case 3: Dilated sinusoid in the femoral head. Air bubbles and agglutination thrombus (arrow) are seen in the lumen. x50.

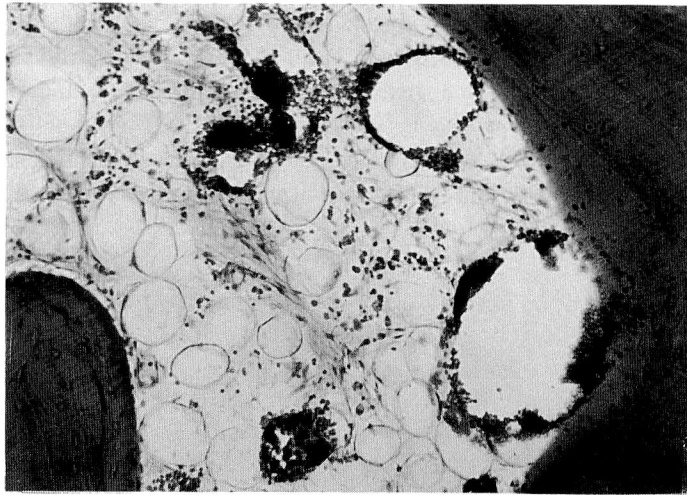


Fig. 5. Case 4: Fibrotic area of femoral head. Slight hemorrhage and phagocytic migration are seen in it. x50.

Experimental Hypercoagulability in DCS

In 1978 Kitano & Kawashima succeeded in producing DCS in experimental rats. Ten male rats were subjected to a hyperbaric exposure of two hours at 6 atm abs and were quickly decompressed to ambient pressure in five minutes. Platelets were counted before compression and after decompression. Thrombelastographical examination was performed in three rabbits which was subjected to a hyperbaric exposure of one hour at 6 atm abs and decompressed in five minutes to ambient pressure.

Before compression, the average number of platelets was $569,700/\text{mm}^3$. After decompression, the average number of platelets was $491,300/\text{mm}^3$. A statistically significant reduction of the number of platelets was seen (Fig. 6).

Thrombelastographs in the rabbits showed the shortening of k and r and the widening of ma after decompression, and this finding indicates the breakdown of platelets (Fig. 7).

Dysbaric Osteonecrosis in Sheep

Since 1985 when Lehner and Lanphier at the University of Wisconsin (U.S.A) had succeeded in producing dysbaric osteonecrosis in sheep long bone, Kitano and others performed a histopathological evaluation of the dysbaric osteonecrosis in sheep as the part of cooperative research in UJNR.

Six, 2-year-old, crossbred female sheep underwent a series of 29-30 hyperbaric exposures of 0.5 to 4 hours duration over a 2.5 year period. The maximum pressure of the hyperbaric exposures reached 2.68 atm abs in the 4 hour exposures and 4.31 atm abs in the 0.5 hour exposures.

Macroscopic Findings: Sectioned bone specimens from the sheep femora contained fatty marrow necrosis which is a common finding in dysbaric osteonecrosis. Fatty marrow necrosis appeared as opaque, shiny, yellow-white inclusions in the marrow cavity (Fig. 8).

Histological Findings: Focal liquefaction of fat occurred in the necrotic lesion. Endo-

Platelet Count ($\times 10^4 / \text{mm}^3$)

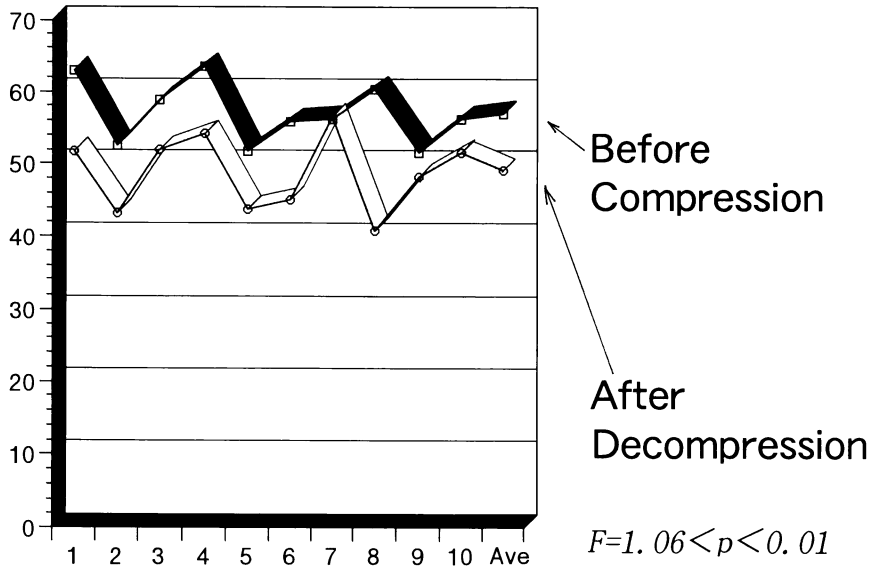



Fig. 6. A significant reduction of the number of platelets is seen after decompression in rats (Kitano).



Thrombelastograph of a rabbit.
Venous blood before compression.



Thrombelastographs of same rabbit as left.
After decompression.
A: arterial blood.
V: venous blood.

(KITANO, LEHNER, KAWASHIMA)

Fig. 7. Thrombelastographs in the rabbit show the breakdown of platelets after decompression (Kitano and Kawashima, 1978).

steal new bone formation was present in the cortical bone. Necrotic fatty marrow is surrounded by a fibro-osseous layer. Individual necrotic fat cells were enveloped by basophilic material of calcified tissue (Fig. 9).

Articular cartilage appeared intact. The histological findings were also essentially identical to those found in Japanese diver's dysbaric osteonecrosis which was reported by Kawashima (1976) and Kitano (1976). However in divers, the prevalence of necrotic foci

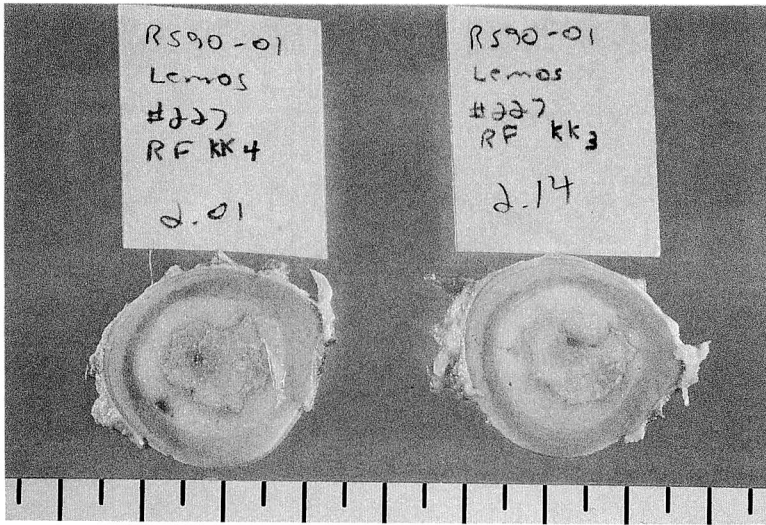


Fig. 8. Fatty marrow necrosis in the transverse section of the distal shaft of the femur of sheep #227 (Kitano, *et al.*, 1993).

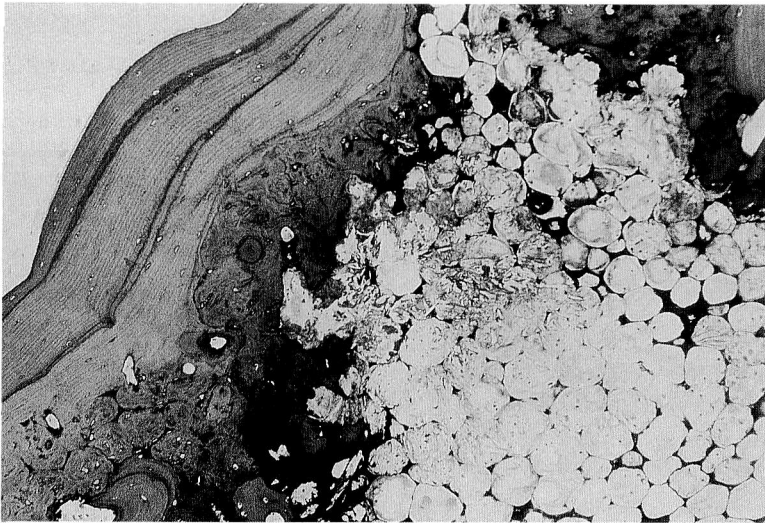


Fig. 9. Necrotic fatty marrow is surrounded by a fibro-osseous layer. Individual necrotic fat cells are enveloped by basophilic material (calcified tissue). Methylene blue and basic fuchsin, x750 (Kitano, *et al.*, 1993).

appeared to be almost as high in the femoral heads as in the distal femoral shafts.

Discussion

The etiology of dysbaric osteonecrosis still remains controversial. Osteonecrosis associated with fat embolism of bone was first demonstrated clinically by Jones in 1965 and first confirmed experimentally by Jones in 1966. In our Case 2, and accumulation of fat and

aggregation of platelets were noted in the vicinity of air bubbles, and fat emboli were seen in the lung vessels. Jones proposed three mechanisms which would be potentially capable of producing intraosseous fat embolism and of triggering a process leading to focal intravascular coagulation and osteonecrosis (Fig. 10).

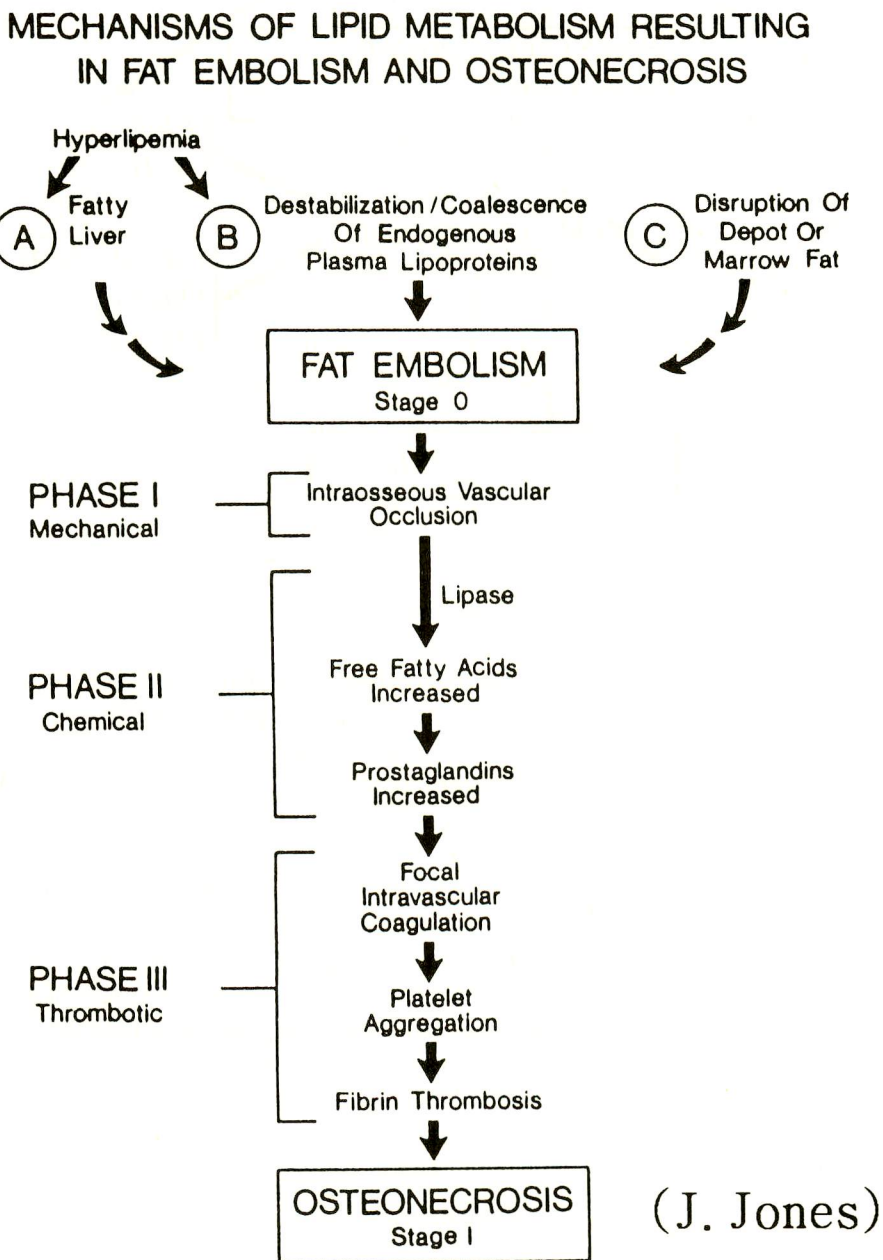


Fig. 10. Schematic representation of three mechanisms potentially capable of producing intraosseous fat embolism and triggering a process leading to focal intravascular coagulation and osteonecrosis. (Jones, 1985).

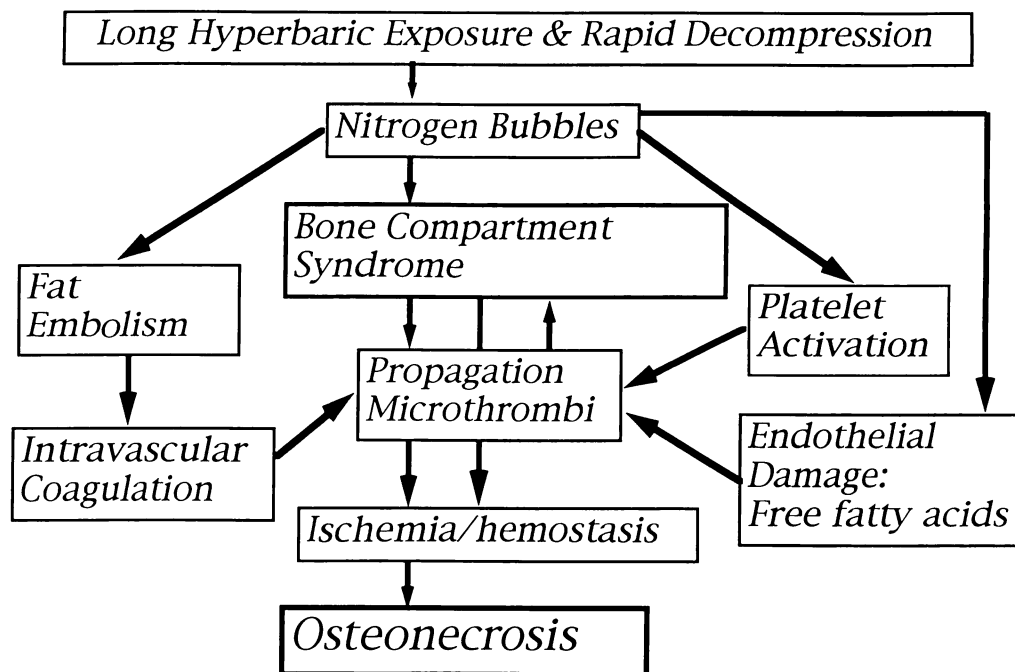


Fig. 11. Pathogenesis of dysbaric osteonecrosis.

In our experimental DCS in rats, a marked reduction of the number of circulating platelets after decompression was observed. Intraosseous hypercoagulation and fat emboli appeared to be factors also important in the pathogenesis of dysbaric osteonecrosis.

Lehner and Lanphier have proposed a bone compartment syndrome as the primary mechanism in the early pathogenesis of dysbaric osteonecrosis. Nitrogen is about five times more soluble in fat than in water. As Behnke observed, the cortical bone surrounding fatty marrow establishes a semi-closed compartment with a complex vasculature potentially vulnerable to vascular obstruction due to bubble formation.

Hypercoagulation and thrombosis in long bone sinusoids would increase bone marrow pressure and promote a bone compartment syndrome (Fig. 11).

Lehner has proposed prompt recompression therapy to prevent or block the development of dysbaric osteonecrosis. Increased ambient pressure in recompression will reduce the volume of any bubbles within the marrow cavity and thereby decrease tissue pressure within the marrow cavity and thereby decrease tissue pressure within the long bones.

Another proposed therapy to prevent or block the development of dysbaric osteonecrosis involves anticoagulants. Anticoagulants might prevent dysbaric osteonecrosis if it is administered at the time of prompt recompression therapy for limb bends.

Conclusions

- 1) Prolonged hyperbaric exposures permit the substantial accumulation of dissolved nitrogen in the fatty marrow of the long bones.
- 2) Decompression may form bubbles in the semi-closed compartment of the long bone. If significant numbers of bubbles form, tissue pressures can rise and ischemia may result.

Persistent limb bends may reflect elevated bone marrow pressure and ischemia in the long bones. If the ischemia is sustained, then dysbaric osteonecrosis may result.

- 3) Persistent ischemia may occur by the proposed mechanism of a bone compartment syndrome in the development of dysbaric osteonecrosis.
- 4) A bone compartment syndrome may be promoted by intraosseous hypercoagulation and fat embolism. These factors appears to be the pathogenetic mechanisms most likely responsible for dysbaric osteonecrosis.
- 5) Early recompression therapy together with anticoagulant therapy may prevent the development of dysbaric osteonecrosis.

References

- Amako, T. and Kawashima, M. 1974. Bone and joint lesions in decompression sickness. *Seminars Arthr Rhenm* 4: 151-190.
- Behnke, A. R. 1945. Decompression sickness incident to deep-sea diving and high altitude ascent. *Medicine* 24: 381-402.
- Elliot, D. H. and Kindwall, E. P. 1982. Manifestations of decompression disorders, In the physiology and medicine of diving (Ed. by Bennet P. B. and Elliot D. H.), Bailliere Tindall, London, pp. 461-472.
- Grutzmacher, K. T. 1941. Veranderungen an Schultergelenk als Folge von Drucklufterkrankung. *Rontgenpraxis (Leipzig)* 13: 216-218.
- Jones, J. P. 1965. Systemic fat embolism after renal hemotransplantation and treatment with corticosteroids. *N, Engl. J, Med.* 273: 1453-1458.
- Jones, J. P. and Sakovich, L. 1966. Fat embolism of bone. A roentgenographic and histological investigation, with use of intra-arterial Lipiodol, in rabbits. *J, Bone Joint Surg.* 48A: 149-164.
- Jones, J. P. Jr. 1985. Fat embolism and osteonecrosis. *Orthop. Clin North Am* 16: 595-633.
- Jones, J. P. Jr. 1992. Intravascular coagulation and osteonecrosis. *Clin Orthop* 277: 41-53.
- Kawashima, M. and Kitano, M. 1977. Histopathology of the early stage of osteonecrosis in divers. *Undersea Biomedical Research* 4: 409-417.
- Kawashima, M. and Kitano, M. 1978. Pathological review of osteonecrosis in divers. *Clin Orthop* 130: 107-117.
- Kawashima, M. 1976. Aseptic bone necrosis in Japanese divers. *The Bulletin of Tokyo Medical and Dental University* 23: 71-92.
- Kitano, M. Kawashima, M. Torisu, T. and Hayashi, K, 1976. A case report of diver with multiple aseptic bone necrosis. *Clin. Orthop (Japan)* 11: 1092-1099.
- Kitano, M. and Kawashima, M. 1978. Experimental studies on decompression sickness. *Orthopedics and Traumatology.* 27: 653-658.
- Kitano, M. and Hayashi, K. 1981. Acute decompressio sickness. *Acta Pathol. Jpn.* 31: 269-276.
- Kitano, M. Lehner, C. E. Kawashima, M. Taya, Y. and Lanphier, E. H., 1993. Experimentally induced dysbaric osteonecrosis in sheep, a histopathological analysis. *South Pacific Study* 13: 173-182.
- Lehner, C. E. 1992. Dive profiles and adaptation: pressure profiles target specific tissues for decompression injury, in *Repetitive Diving Workshop* (Eds M. A. Lang and R. D. Vann), 203-217, American Academy of Underwater Sciences, Costa Mesa, California.

- Lehner, C. E., Adler, G. G., Kanikula, T. M., Palta, M. and Lanphier, E. H. 1985. Influence of dive profile on manifestations of decompression sickness. *Undersea Biomed. Res.* 12 (suppl): 12.
- Lehner, C. E., Palta, M., Adler, G. G., Lightfoot, E. N. and Lanphier, E. H. 1985. Prediction of DCS incidence from no-stop decompression air dives. *Undersea Biomed. Res.*
- Lehner, C. E., Hei, D. J., Palta, M., Lightfoot, E. N. and Lanphier, E. H. 1986. Accelerated onset of decompression sickness in short, deep dives in sheep. In: *Ninth Symposium on Underwater Physiology (program abstracts)* (Kobe, Japan, September, 1986). Bethesda: Undersea Medical Society.
- Lehner, C. E., Hei, D. J., Palta, M., Ives, T. M. and Lanphier, E. H. 1987. Dive profile selectively influences the relative frequency of decompression sickness manifestations. *Undersea Biomed. Res.* 14 (Suppl): 17.
- Lehner, C. E., Cronk, B. C., Hei, D. J., and Lanphier, E. H. 1988. Transient decompression sickness in sheep: Implications for human cases. *Undersea Biomed. Res.* 15 (Suppl): 68.
- Lehner, C. E., Hei, D. J., Kang, Y. and Lanphier, E. H. 1989. Statistical associations of decompression sickness manifestations in sheep: implications for human cases. *Undersea Biomed. Res.* 16 (Suppl): 91-92.
- Lehner, C. E., Lanphier, E. H., Lemos, S. E., Adams, W. M. 1990. Dysbaric osteonecrosis and elevated pressure: a proposed etiological and pathogenic model. *Undersea Biomed. Res.* 17 (Suppl): 29.
- Lehner, C. E., Lin, T. F., Rhode, B. A., Dubielzig, R. R., Shidara, F. and Lanphier, E. H. 1991. Respiratory decompression sickness in sheep after prolonged hyperbaric exposure: obesity as a risk factor in chokes. *Undersea Biomed. Res.* 18 (Suppl): 71-72.
- Lehner, C. E., Lin, T. F., Lanphier, E. H., Wilson, M. A., Markel, M. D. and Dueland, R. 1993. Prolonged hyperbaric exposure, persistent limb bends, and early recompression treatment in dysbaric osteonecrosis. *Undersea and Hyperbaric Med.* 20 (Suppl): 21.