

Immunohistochemical Analysis of Thymidine Phosphorylase Overexpression in Malignant Lymphomas (ML), Especially in Adult T-cell Leukemia/Lymphoma (ATLL)

Kazuhisa Hasui[1], Eiichi Sato[1], Masaki Kitazono[2,3], Shin-ichi Akiyama[2], Yuetsu Tanaka[4], Michiyo Higashi[1], Chiaki Taki[1], Akiko Sakoda[1], Yukie Tashiro[5] and Hiroshi Shirahama[5]

[1]Second Department of Pathology, [2]Institute for Cancer Chemotherapy, and [3]First Department of Surgery, Faculty of Medicine, Kagoshima University, Sakuragaoka, Kagoshima, [4]Department of Bioscience, School of Science, Kitasato University, Kitasato, Sagamihara, Kanagawa, and [5]Department of Pathology. Imakiire General Hospital, Shimotatsuo-cho, Kagoshima, Japan

In order to see whether Thymidine phosphorylase (TP)-positive lymphomas exist and whether there is relation between overexpression of TP and HTLV-1 infection, overexpression of TP/Platelet-derived endothelial cell growth factor (PD-ECGF) was examined in 59 cases of malignant lymphomas (ML) by means of Elite avidin-biotin complex method employing anti-TP monoclonal antibody. The 59 cases of ML comprised 20 nodal peripheral T-cell lymphomas (npT-ML), 10 extranodal peripehral T-cell lymphomas (epT-ML), 18 B-cell lymphomas (B-ML), 10 Hodgkin's diseases (HD), and one true histiocytic lymphoma. Fifteen cases of peripheral T-cell lymphoma (pT-ML) including TP-positive cases, which were mentioned below, were examined in a point of HTLV-1 proviral DNA integration by means of polymerase chain reaction (PCR) and in a point of expression of HTLV-1 Tax preotein by means of modified ImmunoMax employing anti-HTLV-1 Tax monoclonal antibody, WATM-1. Only in three cases of epT-ML, TP-positive lymphoma cells were recognized. The three TP-positive epT-MLs were of ATLL expressing HTLV-1 Tax, as the most cases of ATLL did. Considering long survival time and smoldering clinical course in spite of high grade histology, two cases of the TP-positive ATLL in the skin might be of an unique clinical entity of ATLL and suggested that overexpression of TP in ATLL was a favorable feature. In the MLs other than the TP-positive ATLL, TP-positive cells were dominantly dendritic cells (DC) including lymphoid dendritic cells (LDC), Langerhans cells (LC), veiled cell (VC) and interdigitating dendritic cells (IDC). It was not clear that follicular dendritic cells (FDC) was positive for TP, although one case of B-ML associated many TP-positive dendritic cells. TP-positive LDCs were seen dominantly in T-zone lymphoma, B-MLs and in HD lymphocytic predominance. TP-positive IDCs forming mesh-like reticular work were noted in AILD type, pleomorphic type and anaplastic large cell type of pT-ML and HD mixed cellularity and lymphocytic depletion. In three cases of B-ML increase of spindle cells revealing nuclear stain of TP was noted. Epithelioid cells in T-cell lymphoepithelioid cell lymphoma and in MATL type B-cell lymphoma were positive for TP. Only in one case of 10 AILD type npT-ML endothelial cells were positive for TP. Most DCs and epithelioid cells were labeled by TP so that TP may be a lineage marker of T-cell associated DC. On the other hand, the cytoplasmic TP in IDC forming mesh-like reticular work in AILD type, high-grade pT-MLs and HD would be induced under cytokines from lymphoma cells and suggested TP's effects on developing processes of IDC.

Key words: Thymidine phosphorylase, immunohistochemistry, T-cell associated dendritic cell, malignant lymphoma, ATLL, HTLV-1, p40Tax, ImmunoMax

Table 1, Number of cases examined

	Number of cases		
T-cell malignant lymphoma (T-ML)	30		
T-zone malignant lymphoma (TzML)		4	
AILD type T-cell lymphoma (AILD type)		6	
Lymphoepithelioid cell lymphoma (LeL)		1	
T-cell pleomorphic lymphoma (Pleo)		13	
small cell type(S)			2
medium-sized cell type (M)			1
medium-sized and large cell type (M/L)			3
large cell type (L)			7
Anaplastic large cell lymphoma (ALCL)		6	
B-cell malignant lymphoma (B-ML)	18		
MALT type lymphoma (MALT)		2	
Immunocytoma (IC)		3	
Monocytoid B-cell lymphoma (MoBL)		1	
Centroblastic lymphoma (CB)		12	
Hodgkin's disease (HD)	10		
Lymphocytic predominance (LP)		2	
Nodular sclerosis (NS)		1	
Mixed cellularity (MC)		5	
Lymphocytic depletion (LD)		2	
Histiocytic lymphoma	1		

AILD type: Angioimmunoblastic lymphadenopathy with dysproteinemia type MALT: Mucosa-associated lymphatic tissue

Introduction

Thymidine phosphorylase (TP) has been named as platelet-derived endothelial cell growth factor (PD-ECGF) (Furukawa et al, 1992: Usuki et al, 1992) or gliostatin (Asai et al, 1992) and has various functions, regulating thymidine pool in a nucleus, increasing thymidine uptake in endothelia of blood vessels, decreasing thymidine uptake in glial cells, synovial cells and fibroblasts, elongating axon of nerve cells in cerebral cortex, stopping apoptosis of cerebral cortex nerve cells, and inducing angiogenesis. The angiogenesis of TP depends on 2-deoxy-d-ribose, one of the degradation products of thymidine and moving blood vessel endothelial cells to form a capillary (Haraguchi et al, 1995). Recently it is suggested in human solid cancers that TP expressed in cancer cells induces angiogenesis in the areas with cancer cell invasion (Moghaddam et al, 1995: Takebayashi ey al, 1995, Toi et al, 1995: Maeda et al 1996, Takebayashi et al,1996).

The activity of TP was reported to be increasing in B-cell and myelocytic cell lines, high in peripheral B cells, low in peripheral T-cells and deficient in T-cell lines (Strivastava et al, 1983). In malignant lymphomas (MLs) the activity of TP was reported to be high in Hodgkin's disease (HD) but not in Burkitt's lymphoma and lymphoblastic lymphoma (Vezzoni et al, 1984). Recently, expression of TP could be detected by immunohistochemistry in macrophages, stromal cells, endothelium, duct epithelium, fibroblasts, glia, renal tubules, squamous cells, epidermal squamous cells and Hassals corpuscles in human normal tissue (Fox et al, 1995).

On the other hand, human T-cell leukemia virus type 1 (HTLV-I) induces adult T-cell leukemia/lymphoma (ATLL) (Takatsuki et al, 1992). We have been developing highly sensitive immunohistochemistry (modified ImmunoMax) (Hasui et al, 1997 in DC Vol.7: 1997) to detect HTLV-1 p40Tax protein (Tax) that play the central role in the leukemogenesis of ATLL (Yoshida & Fujisawa, 1992).

This study aimed to see what kinds of cells show expression of TP in MLs, to find whether ATLL cells express TP, and to understand the relationship between expression of HTLV-1 Tax and TP in TP-positive ATLL if exists.

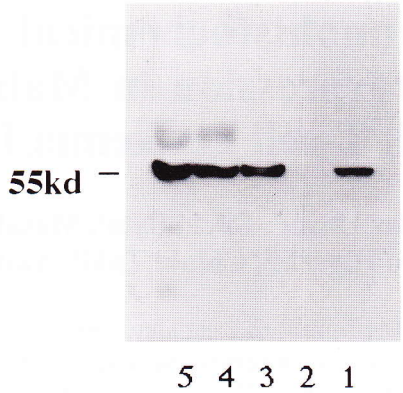

FIGURE 1. Western bot analysis employing the anti-tymidine phosphorylase (TP) monoclonal antibody that was used in this study
Lane 1: SW620 cell line transfected with TPcDNA
Lane 2: KB-3-1 cell line transfected with control vector
Lane 3: KB-3-1 cell line transfected with TPcDNA
Lane 4: Extract from human lymph node with necrotizing lymphadenitis
Lane 5: Extract from the other hyman lymph node with necrotizing lymphadenitis
SW620 (Lane 1) and KB-3-1 cell lines (Lane 3) transfected with TP cDNA expressed TP of 55 kd molecular weight, whereas TP was not dected in KB-3-1 cell line (Lane 2) transfected with control vector. In two lymph nodes with necrotizing lymphadenitis (Lane 4 and 5) TP was detected at the same molecular weight.

Material and method

Material employed are paraffin sections of 30 cases of peripheral T-cell malignant lymphomas (pT-MLs) including 10 cases of extranodal cases, 18 cases of B-cell malignant lymphomas (B-MLs) including three cases of extranodal cases, 10 cases of Hodgkin's disease (HD) and one case of true histiocytic lymphoma. These pT-MLs, B-MLs, HD and true histiocytic lymphoma were diagnosed, based on immunohistochemistry by means of avidin-biotin complex (ABC)

Table 2, Thymidine phosphorylase positive cells in malignant lymphomas

(No. of cases with TP-positive cells/No. of cases examined)

	ML cell	Lymphoid cell	Spindle cell	Dendritic cell	Endothelial cell
T-cell ML	**3/30**	**8/30**	**10/30**	**24/30**	**3/30**
Nodal	0/20	5/20	9/20	15/20	3/20
Extranodal	3/10	3/10	1/10	9/10	0/10
B-cell ML	**0/18**	**16/18**	**3/18**	**7/18**	**0/18**
MALT type	0/2	2/2	2/2	1/2	0/2
Hodgkin's disease	**0/10**	**4/10**	**3/10**	**5/10**	**0/10**
Histiocytic	**0/1**	**1/1**	**0/1**	**0/1**	**0/1**

ML cell: Lymphoma cell. Lymphoid cell: Lymphoid cells other than lymphoma cells, corresponding lymphoid dendritic cells (LDC). Spindle cell: Intermediate form of veiled cell (VC) to interdigitating dendritic cell (IDC). Dendritic cell: Dendritic cell (DC) and IDC. Endothelial cell: Endothelial cells in high endothelial vessels

Table 3, Thymidine phosphorylase positive cells in nodal T-cell malignant lymphomas

	ML cell		Lymphoid cell		Spindle cell		Dendritic cell			Endothelial cell		
	C	N	C	N	C	N	C	N	D	C	N	D
1, TzML	-	-	-	+	-	-	-	-	-	-	-	-
2,	-	-	-	+	-	-	-	-	-	+/-	-	++
3,	-	-	-	+/-	-	-	++	+	++	-	-	-
4,	-	-	-	+/-	+	++	-	-	-	-	-	++
5, AILD type	-	-	-	+/-	-	-	++	-	mesh	-	-	++
6,	-	-	-	-	+	+	++	+	++	-	-	++
7,	-	-	-	-	-	-	++	++	mesh	-	-	++
8,	-	-	-	-	-	-	++	+	mesh	-	-	++
9,	-	-	-	-	-	-	++	++	mesh	+	+	++
10,	-	-	-	-	-	+	-	-	-	-	-	++
11, LeL	-	-	-	-	+	+	++	++	cluster	-	-	-
12, Pleo, S	-	-	-	-	+	++	+	++	++	-	-	-
13, , M/L	-	-	-	-	-	+	+	++	++	+	+	++
14, , M/L	-	-	-	-	-	-	++	++	mesh	-	-	-
15, , L	-	-	-	-	-	-	++	++	mesh	-	-	-
16, , L	-	-	-	-	+/-	++	-	-	-	-	-	-
17, , L	-	-	-	-	-	-	++	++	mesh	-	-	-
18, , L	-	-	-	-	-	-	+/-	++	++	-	-	-
19, ALCL	-	-	-	-	+	+	+	++	++	-	-	++
20, ALCL	-	-	-	+	+	++	+	++	++	-	-	-

ML cell: Lymphoma cell. Lymphoid cell: Lymphoid cells other than lymphoma cells, corresponding lymphoid dendritic cells (LDC). Spindle cell: Intermediate form of veiled cell (VC) to interdigitating dendritic cell (IDC). Dendritic cell: Dendritic cell (DC) and IDC. Endothelial cell: Endothelial cells in high endothelial vessels C: Cells with thymidine-phosphorylase cytoplasmic stain N: Cells with thymidine-phosphorylase nuclear stain

Number of TP positive cells

-: No positive cells, +/-: A few positive cells, +: Some positive cels, ++: Many positive cells

D in Dendritic cell: Number of Dendritic cells and distribution pattern of TP-positive cells, cluster: Clustering of dendritic cells including epithelioid cells. mesh: Mesh-like reticular distribution.

D in Endothelial cell: Number of high endothelial vessels according to the grading presented above.

method employing anti-T-cell monoclonal antibodies, MT-1, UCHL-1 and OPD4, anti-B-cell monoclonal antibodies, L26, Mx-pan B, anti-immunoglobulin kappa and lambda type light chain antibodies, anti-HD cells and CD30 antigen antibody (BerH2), anti-muramidase antibody and anti-S100 protein antibody. These pT- and B-MLs were categorized according to the updated Kiel classification (Lennert & Feller, 1990), as shown in table 1. HDs were classified according to the Rye classification.

TP was detected by Elite-ABC method, as following. After dewax, destruction of endogenous peroxidase's activity in 3% H_2O_2 methanol for 10 min. and block of non-specific binding of antibody by incubating sections in 4% horse serum antibody dilution solution, anti-TP monoclonal antibody (MoAb) is applied to the sections. The reacted anti-TP MoAb was detected by means of Elite-ABC method. The employed anti-TP MoAb could label the band of TP extracted from SW620 and KB31 cell line with TP gene-transfection and from human lymph node fresh tissue with necrotizing lymphadenitis at 55kd length (Fig. 1). Positive stain of anti-TP MoAb was differentiated as cytoplasmic and nuclear in each kind of TP-positive cells under microscope. Number of TP positive cells was graded in four; no positive cells (-), a few positive cells (+/-), some positive cells (+) and many positive cells (++). The distribution pattern of TP-positive dendritic cells was expressed as cluster or mesh-like reticular (mesh).

Fifteen cases of the 30 pT-MLs were examined in integration of HTLV-1 proviral DNA by means of polymerase chain reaction (PCR) employing a set of primers of SK43-44 for HTLV-1 proviral DNA pX region and in the expression of HTLV-1 Tax by means of the modified ImmunoMax (Hasui et al, DC Vol.7, 1997) employing anti-Tax rat MoAb, WATM-1, as reported previously (Hasui et al, DC Vol.7, 1997: 1997). The DNA extracted from the paraffin-section was examined by PCR of a pair of primers PC03-04 for human β-globin gene to see whether the extracted DNA was adequate for the PCR analysis. And the pT-MLs showing a band of the 159 bp long amplified DNA in the PCR for HTLV-1 proviral DNA pX region were treated as ATLL. After dewaxed, antigen retrieval by incubating sections in 4M urea solution for 5 min. at about 110℃ by means of high pressure cookpot, block of non-specific binding of antibodies by incubating sections in non-fat milk solution with horse se-

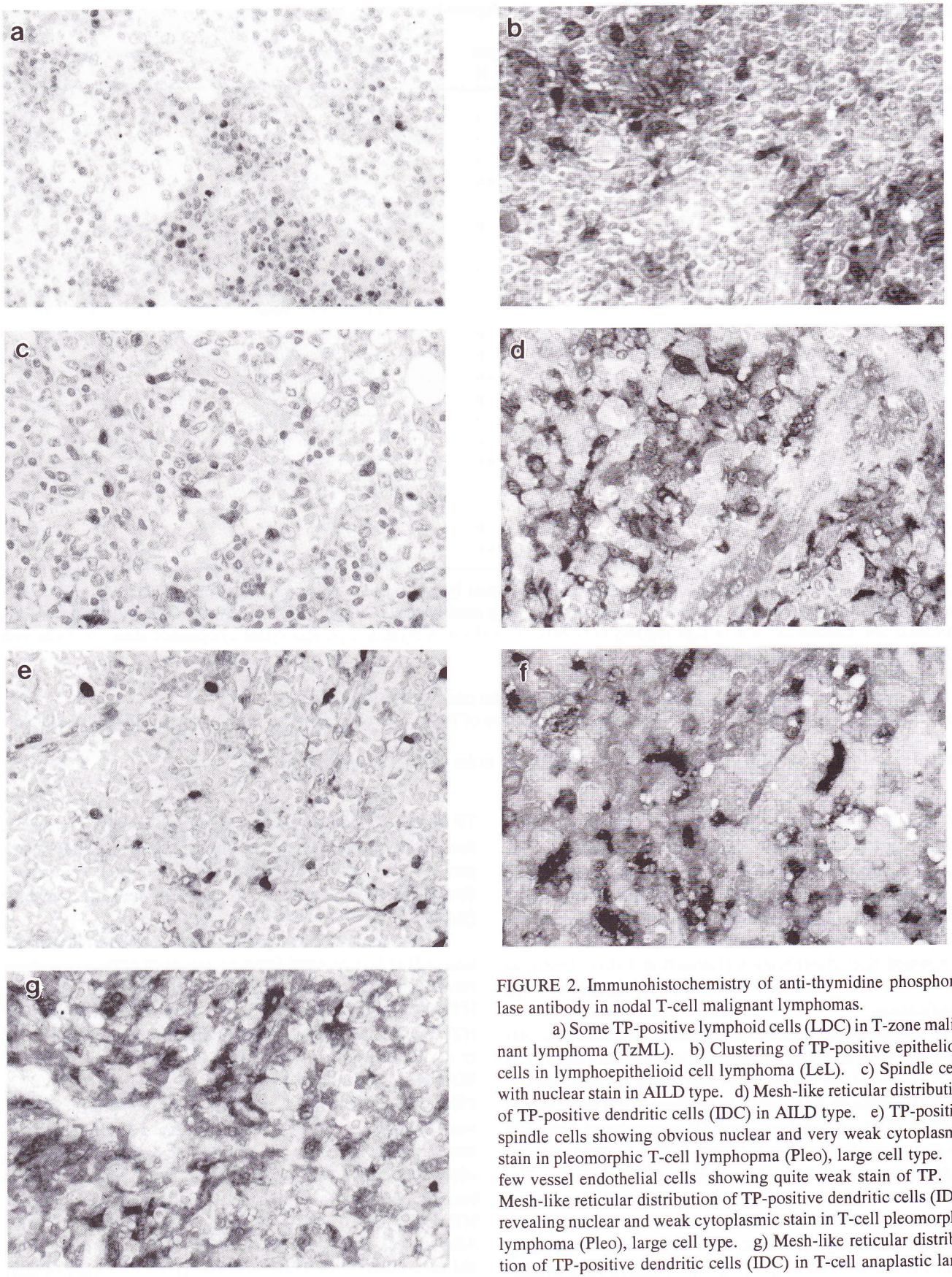

FIGURE 2. Immunohistochemistry of anti-thymidine phosphorylase antibody in nodal T-cell malignant lymphomas.

a) Some TP-positive lymphoid cells (LDC) in T-zone malignant lymphoma (TzML). b) Clustering of TP-positive epithelioid cells in lymphoepithelioid cell lymphoma (LeL). c) Spindle cells with nuclear stain in AILD type. d) Mesh-like reticular distribution of TP-positive dendritic cells (IDC) in AILD type. e) TP-positive spindle cells showing obvious nuclear and very weak cytoplasmic stain in pleomorphic T-cell lymphopma (Pleo), large cell type. A few vessel endothelial cells showing quite weak stain of TP. f) Mesh-like reticular distribution of TP-positive dendritic cells (IDC) revealing nuclear and weak cytoplasmic stain in T-cell pleomorphic lymphoma (Pleo), large cell type. g) Mesh-like reticular distribution of TP-positive dendritic cells (IDC) in T-cell anaplastic large cell lymphoma (ALCL).

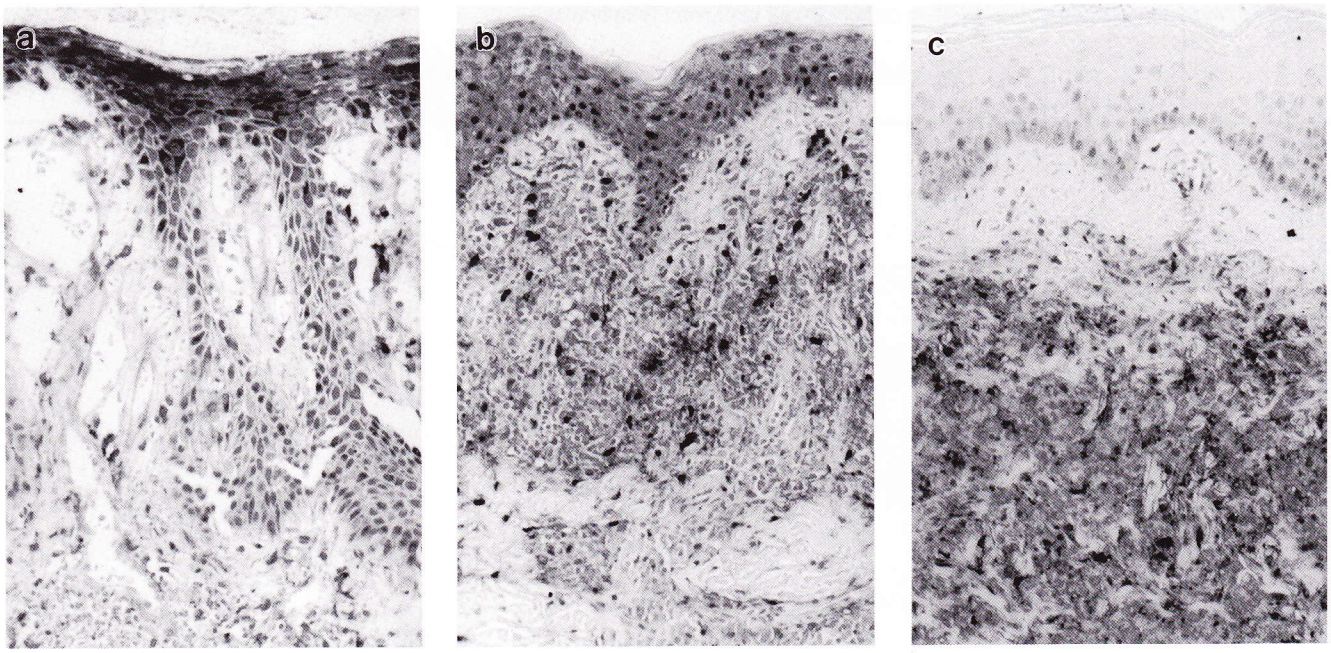

FIGURE 3, Immunohistochemistry of anti-thymidine phosphorylase antibody in extranodal T-cell malignant lymphomas
a) TP-positive epidermis and a few TP-positive dendritic cells (probably, Langerhans cells) among inifltrating and proliferating lymphoma cells. b) Epidermal squamous cells revealing nuclear stain and some TP-positive dendritic cells (probably, Langerhans cells) among lymphoma cells. c) Lymphoma cells revealing cytoplasmic and nuclear stain of TP

Table 4, Thymidine phosphorylase positive cells in extranodal T-cell malignant lymphomas

	ML cell		Lymphoid cell		Spindle cell		Dendritic cell			Endothelial cell		
	C	N	C	N	C	N	C	N	D	C	N	D
Skin												
21, T-Pleo, S	-	-	-	+/-	-	-	++	++	++	-	-	-
22, , M	-	-	-	-	-	-	++	++	++	-	-	-
23, . M/L	-	-	-	-	-	-	++	++	++	-	-	-
24, , L	+	+/-	-	-	-	-	++	++	++	-	-	-
25, , L	-	-	-	-	-	-	++	++	++	-	-	-
26, , L	-	-	-	+/-	-	-	+/-	+	+	-	-	-
27, ALCL	++	+	-	+/-	+/-	+/-	+	+	+	-	-	-
28, ALCL	-	-	-	-	-	-	+	++	++	-	-	-
29, ALCL	-	-	-	-	-	-	++	++	++	-	-	-
Lung												
30, ALCL	+/-	++	-	-	-	-	-	-	-	-	-	-

ML cell: Lymphoma cell. Lymphoid cell: Lymphoid cells other than lymphoma cells, corresponding lymphoid dendritic cells (LDC). Spindle cell: Intermediate form of veiled cell (VC) to interdigitating dendritic cell (IDC). Dendritic cell: Dendritic cell (DC) and IDC. Endothelial cell: Endothelial cells in high endothelial vessels C: Cells with thymidine-phosphorylase cytoplasmic stain N: Cells with thymidine-phosphorylase nuclear stain

Number of TP positive cells

-: No positive cells, +/-: A few positive cells, +: Some positive cels, ++: Many positive cells

D in Dendritic cell: Number of Dendritic cells and distribution pattern of TP-positive cells, cluster: Clustering of dendritic cells including epithelioid cells. mesh: Mesh-like reticular distribution.

D in Endothelial cell: Number of high endothelial vessels according to the grading presented above.

Table 5, Thymidine phosphorylase positive cells in B-cell malignant lymphomas

	ML cell		Lymphoid cell		Spindle cell		Dendritic cell			Endothelial cell		
	C	N	C	N	C	N	C	N	D	C	N	D
1, MALT	-	-	-	+/-	-	+/-	+/-	+	+	-	-	-
2,	-	-	-	+/-	-	+	-	-	-	-	-	-
3, IC	-	-	-	+	-	-	-	-	-	-	-	-
4,	-	-	-	+	-	-	-	-	-	-	-	-
5,	-	-	-	+/-	-	-	-	-	-	-	-	-
6, CB	-	-	-	-	-	-	+	+	+	-	-	-
7,	-	-	-	+	-	-	-	-	-	-	-	-
8,	-	-	-	+	-	-	+	+	+	-	-	-
9,	-	-	-	+	-	-	+/-	+	+	-	-	-
10,	-	-	-	+	-	-	-	-	-	-	-	-
11,	-	-	-	+	-	-	-	+	+	-	-	-
12,	-	-	-	-	-	-	-	-	-	-	-	-
13,	-	-	-	+/-	-	-	-	-	-	-	-	-
14,	-	-	-	++	-	-	-	-	-	-	-	-
15,	-	-	-	++	-	-	-	-	-	-	-	-
16,	-	-	-	+	-	-	-	+	+/-	-	-	-
17,	-	-	-	+/-	-	-	-	++	++	-	-	-
18, MoBL	-	-	-	+/-	-	+	-	-	-	-	-	-

ML cell: Lymphoma cell. Lymphoid cell: Lymphoid cells other than lymphoma cells, corresponding lymphoid dendritic cells (LDC). Spindle cell: Intermediate form of veiled cell (VC) to interdigitating dendritic cell (IDC). Dendritic cell: Dendritic cell (DC) and IDC. Endothelial cell: Endothelial cells in high endothelial vessels C: Cells with thymidine-phosphorylase cytoplasmic stain N: Cells with thymidine-phosphorylase nuclear stain

Number of TP positive cells

-: No positive cells, +/-: A few positive cells, +: Some positive cels, ++: Many positive cells

D in Dendritic cell: Number of Dendritic cells and distribution pattern of TP-positive cells, cluster: Clustering of dendritic cells including epithelioid cells. mesh: Mesh-like reticular distribution.

D in Endothelial cell: Number of high endothelial vessels according to the grading presented above.

rum, WATM-1 were applied on the sections. The reacted WATM-1 were labeled by DAKO catalyzed signal amplification (CSA) system with adding rabbit serum in secondary biotinylated anti-rat antibody solution in order to block non-specific binding of the secondary antibody. The degree in the detected expression of HTLV-1 Tax was evaluated as following; no stain (-), weakly positive many lymphoma cells (+/-), positive many lymphoma cells (+) and strongly positive many lymphoma cells (++).

Result

Expression of TP was detected by the anti-TP MoAb in lymphoma cells, lymphoid cells other than lymphoma cells, dendritic cells and blood vessel endothelial cells as indicated in table 2. TP-positive lymphoma cells were seen only in three cases of extranodal pT-MLs. TP-positive lymphoid cells were recognized more frequently in B-MLs (16/18 cases) than in pT-MLs (8/30 cases). Differentiating spindle cells and cells having many dendritic cytoplasmic processes in dendritic cells (RCs), TP-positive RCs were recognized more frequently in pT-MLs than in B-MLs. TP-positive high endothelial cells of blood vessels were seen only in three cases of pT-ML. In the case of true histiocytic lymphoma, a small number of lymphoid cells were positive for TP.

TP-positive cells in peripheral T-cell lymphomas

As shown in Fig. 2, various distributions of TP-positive cells was noted in each subtype of nodal pT-MLs. In T-zone malignant lymphoma (TzML), some or a few lymphoid cells revealing TP in nucleus were noted in the all four cases (Fig. 2a, case 1 in table 3). In the two cases with a few TP-positive lymphoid cells increase of TP-positive spindle cell or dendritic cells was observed. In lymphoepithelioid cell lymphoma (case 11 in table 3), there were clustering TP-positive epithelioid cells (Fig. 2b) that were categorized as dendritic cells in table 3. In angioimmunoblastic lymphadenopathy with dysproteinemia (AILD) type, mesh-like reticular distribution of TP-positive dendritic cells were seen in 4 of 6 cases (Fig. 2d). In one case there were increased spindle cells with TP in nucleus (Fig. 2c, case 10 in table 3). Increase of high endothelial vessels is the representative feature of AILD type, but TP-positive endothelial cells were noted only in one case shown in Fig 3d (case 9 in table 3). In one case, increase of the both TP-positive spindle cells and dendritic cells was recognized (case 6 in table 3). In pleomorphic lymphomas and anaplastic large cell lymphomas, increase with or without mesh-like reticular distribution of TP-positive spindle or dendritic cells was recognized.

Nine of 10 extranodal pT-MLs were of the skin. The

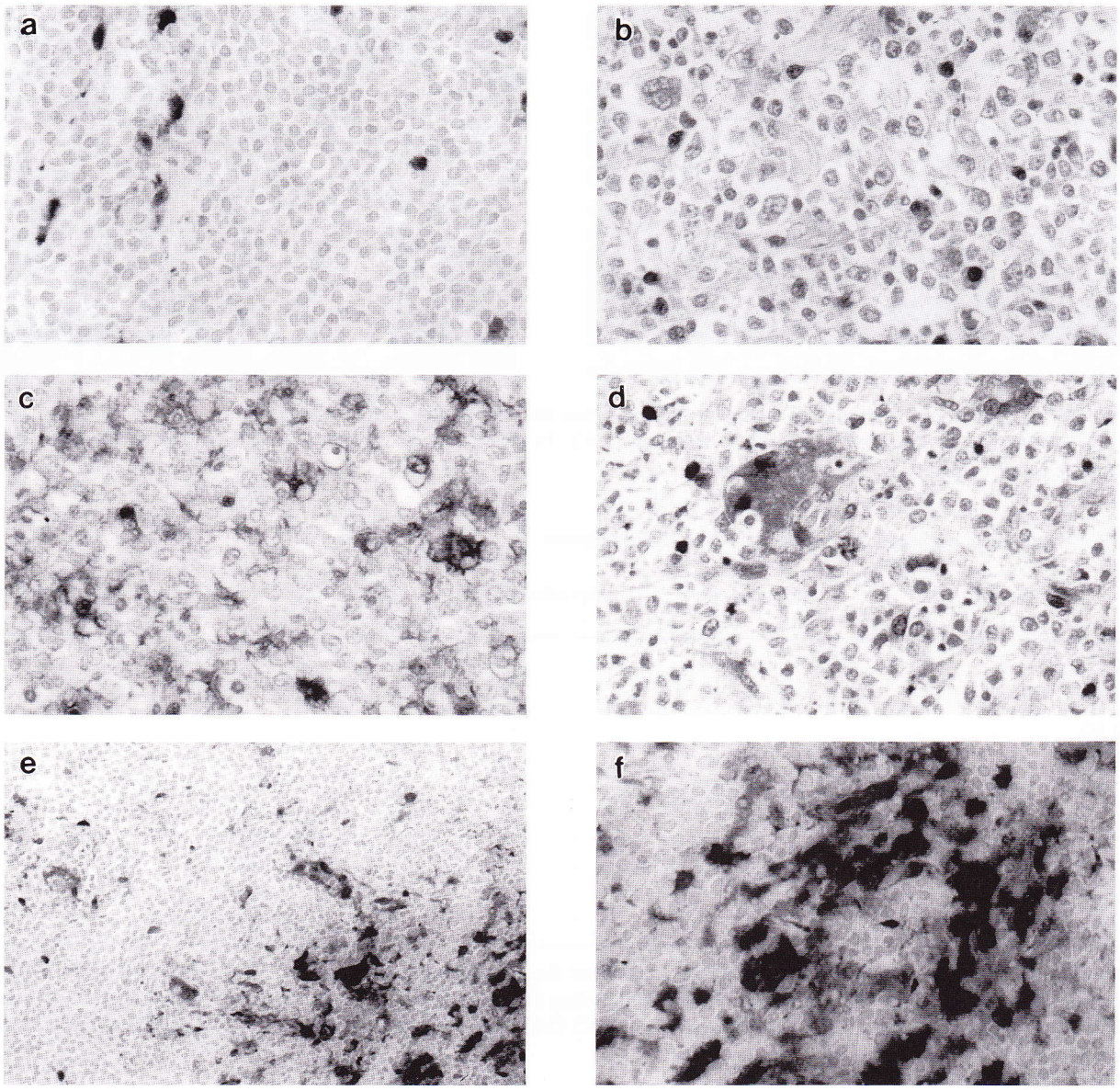

FIGURE 4, Immunohistochemistry of anti-thymidine phosphorylase antibody in B-cell malignant lymphomas
a) TP-positive lymphoid cells in immunocytoma (IC). b) TP-positive lymphoid cells in centroblastic lymphoma (CB). c) Increase of TP-positive dendritic cells showing obviously nuclear and weakly cytoplasmic stain of TP in one case of CB. d) TP-positive epithelioid cells associating lymphocytes in cytoplasm in MALT type lymphoma. e) Clustering of TP-positive spindle cells around blood vessels and in the surrounding area of residual lymph follicle in one case of IC. f) High power view of the e) figure.

epidermal squamous cells showed various TP-positive stains as shown in Fig. 3. Among lymphoma cells there were increased TP-positive dendritic cells (Fig. 3). In three cases, including one case of the lung, lymphoma cells were positive for TP (Fig. 3c, case 24 in table 4). Cytoplasmic TP was seen in more lymphoma cells than intranuclear TP in two cases of the skin, whereas intranuclear TP was seen in many lymphoma cells in the case of the lung (case 30 in table 4).

TP-positive cells in B-cell lymphomas

In most cases of B-MLs there were a small number of TP-positive lymphoid cells other than lymphoma cells (Fig, 4a and b).

In one case of mucosa-associated lymphatic tissue (MALT) type the glandular epithelial cells in lymphoepithelial lesion were positive for TP. In the same case of MALT type there was TP-positive epithelioid cells having lymphocytes in cytoplasm (Fig. 4d). In one case of centroblastic lymphoma, TP-positive dendritic cells increased among lymphoma cells but did not show mesh-like reticular distribution Fig. 4c). In one case of MALT type and in one case of immunocytoma, clusters of TP-positive spindle cells were noted around blood vessels (Fig. 4e and f) and in the surrounding area of the residual lymph follicle.

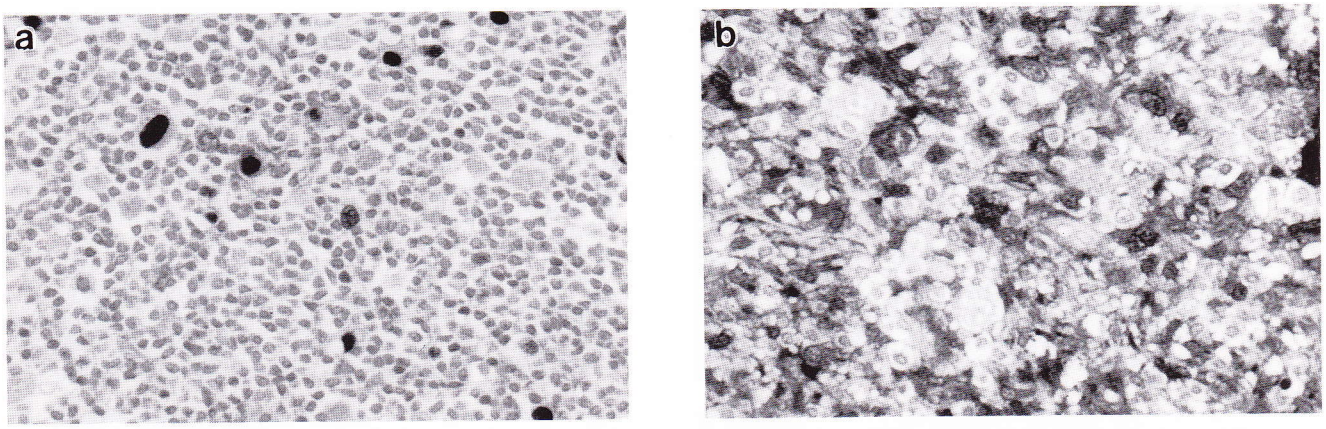

FIGURE 5, Immunohistochemistry of anti-thymidine phosphorylase antibody in Hodgkin's disease (HD)
a) TP-positive lymphoid cells in HD mixed cellularity (MC). b) Mesh-like reticular distribution of TP-positive dendritic cells in HD lymphocytic depletion (LD)

Table 6, Thymidine phosphorylase positive cells in Hodgkin's disease

	ML cell		Lymphoid cell		Spindle cell		Dendritic cell			Endothelial cell		
	C	N	C	N	C	N	C	N	D	C	N	D
1, HD LP	-	-	-	++	-	-	-	-	-	-	-	-
2,	-	-	-	++	-	+	-	-	-	-	-	-
3, HD NS	-	-	-	-	-	+	-	-	-	-	-	-
4, HD MC	-	-	-	++	-	-	-	-	-	-	-	-
5,	-	-	-	+	-	+	-	-	-	-	-	-
6,	-	-	-	-	-	-	+/-	+	+	-	-	-
7,	-	-	-	-	-	-	++	++	mesh	-	-	-
8,	-	-	-	-	-	-	++	++	mesh	-	-	-
9, HD LD	-	-	-	-	-	-	++	++	mesh	-	-	-
10,	-	-	-	-	-	-	++	++	mesh	-	-	-

ML cell: Lymphoma cell. Lymphoid cell: Lymphoid cells other than lymphoma cells, corresponding lymphoid dendritic cells (LDC). Spindle cell: Intermediate form of veiled cell (VC) to interdigitating dendritic cell (IDC). Dendritic cell: Dendritic cell (DC) and IDC. Endothelial cell: Endothelial cells in high endothelial vessels C: Cells with thymidine-phosphorylase cytoplasmic stain N: Cells with thymidine-phosphorylase nuclear stain
Number of TP positive cells
-: No positive cells, +/-: A few positive cells, +: Some positive cels, ++: Many positive cells
D in Dendritic cell: Number of Dendritic cells and distribution pattern of TP-positive cells, cluster: Clustering of dendritic cells including epithelioid cells. mesh: Mesh-like reticular distribution.
D in Endothelial cell: Number of high endothelial vessels according to the grading presented above.

TP-positive cells in Hodgkin's disease

In 10 cases of HD, TP-positive Reed-Sternberg cells and Hodgkin cells were not seen, whereas either TP-positive lymphoid cells (Fig. 5a) or TP-positive dendritic cells (Fig. 5b) were recognized. The TP-positive dendritic cells showed mesh-like reticular distribution in two cases of HD mixed cellularity and in two cases of HD lymphocytic depletion (Fig. 5b).

HTLV-1 Tax in TP-positive and -negative lymphoma cells

In 15 cases of pT-ML comprising 14 cases of ATLL and one case of HTLV-1 negative pT-ML the three extranodal pT-MLs, of which lymphoma cells were positive for TP (in Table 4, Fig. 6a), were of ATLL (Table 7).

In the three TP-positive ATLL, lymphoma showed cytoplasmic granular stain of the modified ImmunoMax of anti-Tax MoAb (Fig. 6b).

Discussion

This study detected TP by means of Elite ABC method so that it is unknown whether physiological expression of TP could be visualized by the Elite ABC method (Mcnicol & Richmond, 1998). For example, epidermal squamous cells indicated various staining pattern in three lesions in Fig. 3, whereas epidermal squamous cells revealing high expression of TP were thought to be important for total body thymidine

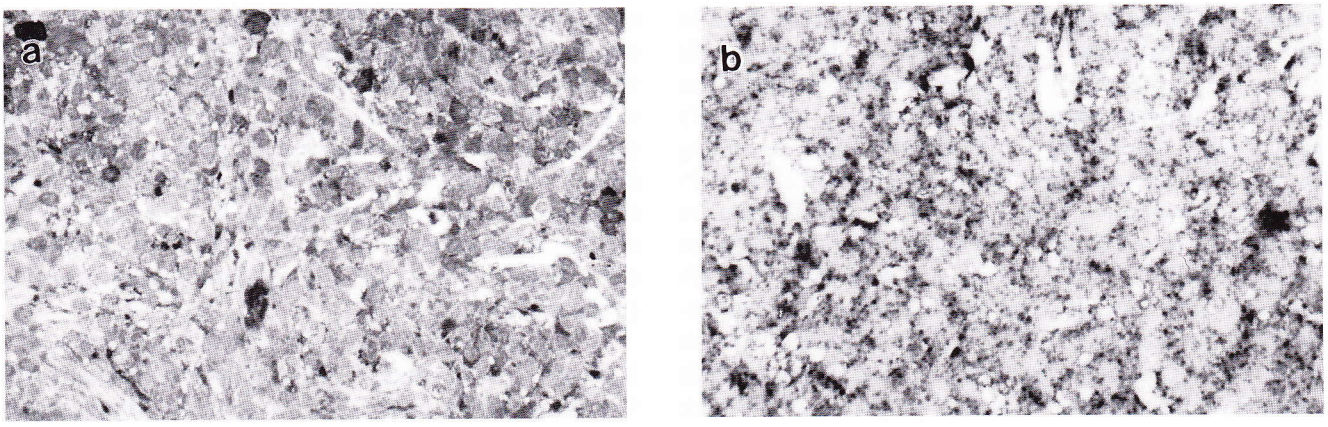

Figure 6, Immunohistochemistry of anti-thymidine phosphorylase and modified ImmunoMax of anti- HTLV-1 Tax antibody, WATM-1.
a) TP-positive lymphoma cells in the skin in the case different from the case presented in Fig. 3c. b) The lymphoma cells indicated expression of HTLV-1 Tax deyecyed by the modified ImmunoMax employing WATM-1.

Table 7, Relation between expression of thymidine phosphorylase and HTLV-1 Tax

Case	Expression of TP in lymphoma cells	PCR for HTLV-1proviral DNA	modified ImmunoMax of HTLV-1 Tax
1, Pleo, M/L	not-expressed	not-amplified	-
2, ALCL	expressed	amplified	+/-
3, Pleo, L	expressed	amplified	+
4, ALCL	expressed	amplified	+
5, ALCL	not-expressed	amplified	-
6, Pleo, S	not-expressed	amplified	+/-
7, Pleo, M/L	not-expressed	amplified	+/-
8, Pleo, L	not-expressed	amplified	+/-
9, AILD type	not-expressed	amplified	+
10, ALCL	not-expressed	amplified	+
11, ALCL	not-expressed	amplified	+
12, ALCL	not-expressed	amplified	+
13, AILD type	not-expressed	amplified	++
14, Pleo, M/L	not-expressed	amplified	++
15, Pleo, L	not-expressed	amplified	++

TP: Thymidine phosphorylase. PCR: Polymerase chain reaction.
amplified: Amplified DNA of the expected 159bp length
not-amplified: DAN of the expected 159bp length was not amplified.
The degree in the detected expression of HTLV-1 Tax; -: No stain, +/-: Weakly positive many lymphoma cells, +: Positive many lymphoma cells, ++: Strongly positive many lymphoma cells

homeostasis (Fox et al, 1995). It meant the possibility to detect overexpression of TP that no lymphoma cells were positive for TP in B-MLs in this study whereas the activity of TP was reported in peripheral B-cells and in B-cell cell lines (Strivastava et al, 1983: Vezzoni et al, 1984). At least, the expression of TP detected by the immunohistochemistry should be evaluated as overexpression.

It was suggested that the expression of TP in nucleus might modulate the pool for DNA synthesis whereas the expression of TP in cytoplasm would control other effects of TP (Fox et al, 1995). Although it was reported that macrophages had strong expression of TP (Fox et al, 1995), this study showed that the macrophages were dendritic cells. In these days dendritic cells are divided in T-cell and B-cell associated dendritic cells, different from monocyte-macrophage system cells revealing phagocytosis, according to Madeda and Imai (1998). The T-cell associated dendritic cells are lymphoid dendritic cell (LDC) in secondary lymphatic tissue, Langerhans cell (LC) in the skin, veiled cell (VC) in lymph vessels, interdigitating cell (IDC) in thymus and lymph node, and dendritic cell (DC) in general organs and in peripheral blood. The B-cell associated dendritic cells comprise follicular dendritic cell (FDC) and antigen transporting cell (ATC). In this study, in pT-MLs and in HD (Tables 3 and 6) increased dendritic cells revealing expression of TP in nucleus and cytoplasm form mesh-like reticular work in the background of lymphoma cell proliferation (Fig. 2), whereas spindle cells (Fig. 2e, case 16 in table 3) and most TP-positive

lymphoid cells showed dominantly the expression of TP in nuclei. In most of the B-MLs TP-positive lymphoid cells were seen (Fig. 4a and b). In a small number of cells there were TP-positive dendritic cells revealing dominantly nuclear stain of TP among B-ML cells (Fig. 4c). According to the nomenclature of dendritic cells mentioned above, TP-positive lymphoid cells were of LDC. The TP-positive spindle cells were thought to be intermediate form between VC and IDC or DC. The TP-positive cells other than TP-positive lymphoma cells could be categories in T-cell and B-cell associated dendritic cells. Then, it was suggested in this study that TP is a good marker of T-cell-associated dendritic cells in lymphoma tissue. Because progenitor of dendritic cell is thought to differentiate to LDC, VC and IDC under GM-CSF and the other cytokines (Asahina & Tamaki, 1998: Takahashi, 1998), increase and mesh-like reticular work of IDC revealing strong TP stain in dendritic cytoplasm in nodal pT-ML suggested that the cytoplasmic TP might effects on development of dendritic processes of IDC, as TP/PD-ECGF/ Gliostain elongates axon of nerve cells. It was unknown whether the TP-positive dendritic cells in one case of B-ML (Fig. 4c) were of FDC or IDC in the T-cell rich background. Further examination about DC in B-cell lymphomas should be necessary to say about TP-positivity in FDC. The well development of IDC with TP expression would be induced by cytokines (Eda et al, 1993: Takebayashi et al, 1995) produced by pT-ML cells. The TP-positive epithelioid cells in a MALT type B-ML (Fig. 4c) may have functions concerning local immunity, because the cell appeared to have lymphocytes in cytoplasm. The increased TP might have effects on a dendritic cell to differentiate to an epithelioid cells.

TP-positive lymphoma cells (Fig. 3c and 6a) were seen only in extranodal ATLL (Tables 4 and 6). As for the origin of TP-positive ATLL cells, there would be the following possibilities, because the activity of TP was reported to be low in peripheral T cells and deficient in T-cell lines (Strivastava et al, 1983). Peripheral T-cells and the cells having high activity of TP, such as B-cells (Strivastava et al, 1983), myeloid cells (Strivastava et al, 1983) and dendritic cells (Fox et al, 1995), might share a bipotential progenitor, as CD5+ macrophages and B-cells may share a bipotential progenitor in vivo in mice (Takahashi et al, 1998). ATLL cell would originate in cell fusion of a peripheral T-cell with HTLV-1 proviral DNA integration and the cells having high activity of TP under the additional viral infection as superimposed infection of Epstein-Barr virus (EBV) in ATLL (Uemura & Tokunaga, 1994). TP might be activated in ATLL cells under HTLV-1 Tax (Yoshida & Fujisawa, 1992) or genetic abnormality under HTLV-1 infection. Abnormal peripheral T-cell with phenotype of dendritic cells may appear in the cytokine-rich microenviroment induced by HTLV-1 infection (Yoshida & Fujisawa, 1992). Although the latter two possibilities would be denied because of no nodal TP-positive ATLL, long survival time more than 4 years in the two cases of TP-positive ATLL in the skin suggested the possibility that does not occur in the usual ATLL revealing a quite short survival. Furthermore, aberrant expression of monocyte/macrophage phenotype was reported in ATLL cell line and in the human T-cell line immortalized by HTLV-1 (Jeon et al, 1994), although its mechanism was not clarified. Each possibility of expression of TP in ATLL cells could not be denied. Although the origin of TP-positive ATLL cells was unknown, at least, the expression of TP in ATLL cells in the skin was thought to be a favorable feature in ATLL because of the long survival of the patients. TP-positive ATLL may be a unique subtype in the smoldering and chronic type of ATLL (Yakatsuki et al, 1992).

Consequently, this study showed that expression of TP is the marker of dendritic cells in malignant lymphoma tissue. Overexpressed TP in IDC may elongate dendritic processes in pT-ML and might IDC form a mesh-like reticular work. There were three cases of TP-positive ATLL in extranodal pT-MLs. In ATLL in the skin the overexpression of TP might be a favorable feature.

Acknowledgment

Authors thank Prof. Shuji Izumo (Department of Molecular Pathology and Genetic epidemiology, Center for Chronic Viral Diseases, Kagoshima University Faculty of Medicine), Dr. Shinji Yashiki and Prof. Shunro Sonoda (Department of Virology, Kagoshima University Faculty of Medicine) and Prof. Mitsuhiro Osame (Third Department of Internal Medicine, Kagoshima University Faculty of Medicine) for their critical and scientific discussion about the highly sensitive immunohistochemistry of anti-HTLV-1-related proteins, p40Tax.

This study was supported in part by a Grant-in Aid from the Ministry of Education (No. C(2) 10670166), by Research on Emerging and Re-emerging Infectious Diseases (Sonoda S.), and by the Program for Promotion of Fundamental Studies in Health Sciences of the Organization for Pharmaceutical Safety and Research (OPSR)(Japan)(Osame M.).

References

Asahina A, Tamaki K. 6. Origin, differentiation and maturation of dendritic cells 2. Langerhans cell, In; Imai Y, Tamaki K, Kasajima T eds. Dendritic Cells. Bunkodou Tokyo 1998; 104-107 (in Japanese)

Asai K, Nakanishi K, Isobe I, Eksioglu YZ, Hirano A, Hama K, Miyamoto T, Kato T. Neurotrophic action of gliostatin on cortical neurons. Identity of gliostatin and platelet-derived endothelial cell growth factor. J Biol Chem. 1992; 267(28): 20311-6

Eda H, Fujimoto K, Watanabe S, Ura M, Hino A, Tanaka Y, Wada K, Ishitsuka H. Cytokines induce thymidine phosphorylase expression in tumor cells and make them more susceptible to 5'-deoxy-5-fluorouridine. Cancer Chemother Pharmacol 1993; 32(5):333-8

Fox SB, Moghaddam A, Westwood M, Turley H, Bicknell R, Gatter KC, Harris AL. Platelet-derived endothelial cell growth factor/ thymidine phosphorylase expression in normal tissues: an immunohitochemical study. J Pathol. 1995; 176(2): 183-90

Furukawa T, Yoshimura A, Sumizawa T, Hasraguchi M, Akiyama S, Fukui K, Ishizawa M, Yamada Y. Angiogenic factor [letter].

Nature 1992;356(6371):668

Haraguchi M, Miyadera K, Uemura K, Sumizawa T, Furukawa T, Yamada K, Akiyama S, Yamada Y. Angiogenic activity of enzyme [letter]. Nature. 1994; 368(6468): 198

Hasui K, Sato E, Tanaka Y, Yashiki S, Izumo S. Quantitative highly-sensitive immunohistochemistry (Modified ImmunoMax) of HTLV-1 p40tax and p27rex proteins in HTLV-1-associated non-neoplastic lymphadenopathy (HANNLA) with estimation of HTLV-1 dose by polymerase chain reaction. DENDRITIC CELLS 1997; 7: 19-27

Hasui K, Sato E, Tanaka Y, Yashiki S, Izumo S. The modified ImmunoMax of HTLV-1 Tax protein can label HTLV-1-related cases in T-cell lymphomas. In: Lee JD, Takahashi K, eds. Lymphoreticular Diseases and Cells, Proceedings of the Fifth Korean-Japanese Lymphoreticular Workshop, Hematolymphoreticular Study Group, the Korean Society of Pathologists, Seoul, Korea, 1997; 326-336

Jeon HJ, Akagi T, Hayashi K, Miyamoto K. Aberrant expression of the monocyte/macrophage phenotype in a human T-cell line immortalized by HTLV-1 and an adult T-cell leukemia/lymphoma cell line. In; Kim SH, Takahashi K eds. Lymphoreticular Cells and Diseases. Proceedings of the third Korean-Japanese Lymphoreticular Workshop. Hematopoietic-Lymphoreticular Study Group, the Korean Society of Pathologists, Seoul, Korea, 1994; 245-263

Lennert K, Feller AC. Histopathology of non-Hodgkin's lymphomas (Based on the updated Kiel classification). 2nd ed. Springer, Berlin, 1990

Maeda K, Chung YS, Ogawa Y, Takatsuka S, Kang SM, Ogawa M, Sawada T, Onoda N, Kato Y, Sowa M. Thymidine phosphorylase/platelet-derived endothelial cell growth factor expression associated with hepatic metastasis in gastric carcinoma. Br J Cancer 1996; 73(8): 884-8

Maeda K, Imai Y. Classification of dendritic cells. In; Imai Y, Tamaoki K, Kasajima T eds. Dendritic Cells. Bunkodou Tokyo 1998; 27-29 (in Japanese)

Mcnicol AM, Richmond JA. Optimizing immunohistochemistry: antigen retrieval and signal amplification. Histopathology 1998;32:97-103

Moghaddam A, Zhang HT, Fan TP, Hu DE, Lees VC, Turley H, Fox SB, Gatter KC, Harris AL, Bicknell R. Thymidine phosphorylase is angiogenic and promotes tumor growth. Proc Natl Acad Sci USA. 1995;92(4): 998-1002

Strivastava BI, Minowada J. Terminal transferase immunofluorescence, enzyme markers and immunological profile of human leukemia-lymphoma cell lines representing different levels of differentiation. Leuk Res. 1983; 7(3): 331-8

Takatsuki K, Yamaguchi K, Watanabe T, Mochizuki M, Kiyokawa T, Mori S, Miyata N. Adult T-cell leukemia and HTLV-1 related diseases. In; Takatsuki K, Hinuma Y, Yoshida M, eds. Advances in adult T-cell leukemia and HTLV-1 Research, Gann Monograph on Cancer Research No. 39, 1992; 1-15

Takebayashi Y, Yamada K, Maruyama I, Fujii R, Akiyama S, Aikou T. The expression of thymidine phosphorylase and thrombomodulin in human colorectal carcinomas. Cancer Lett. 1995; 92(1): 1-7

Takebayashi Y, Yamada K, Ohmoto Y, Sameshima T, Miyadera K, Yamada Y, Akiyama S, Aikou T. The correlation of thymidine phosphorylase activity with the expression of interleukin 1 alpha, interferon alpha and interferon gamma in human colorectal carcinoma. Cancer Lett 1995;95(1-2): 57-62

Takebayashi Y, Miyadera K, Akiyama S, Hokita S, Yamada K, Akiba S, Yamada Y, Sumizawa T, Aikou T. Expression of thymidine phosphorylase in human gastric carcinoma. Jpn J Cancer Res. 1996; 87(3): 288-95

Takahashi K. 6. Origin, differentiation and maturation of dendritic cells 3. interdigitating dendritic cell. In; Imai Y, Tamaki K, Kasajima T eds. Dendritic Cells. Bunkodou Tokyo 1998; 108-112 (in Japanese)

Takahashi K, Miyakawa K, Wynn AA, Nakayama KI, Myint YY, Naito M, Shultz LD, Tominaga A, Takatsu K. Effects of granulocyte/macrophage colony-stimulating factor on the development and differentiation of CD5-positive macrophages and their potential derivation from a CD5-positive B-cell lineage in mice. Am J Pathol 1998; 152(2): 445-56.

Toi M, Hoshina S, Taniguchi T, Yamamoto Y, Ishitsuka H, Tominaga T. Expression of platelet-derived endothelial cell growth factor/thymidine phosphorylase in human breast cancer. Int J Cancer 1995; 64(2): 79-82

Uemura Y, Tokunaga M. Epstein-Barr virus related malignant lymphoma in an endemic area of adult T-cell leukemia. In; Kim SH, Takahashi K eds. Lymphoreticular Cells and Diseases. Proceedings of the third Korean-Japanese Lymphoreticular Workshop. Hematopoietic-Lymphoreticular Study Group, the Korean Society of Pathologists, Seoul, Korea, 1994; 113-120

Usuki K, Saras J, Waltenberger J, Miyazono K, Pierce G, Thomason A, Heldin CH. Platelet-derived endothelial cell growth factor has thymidine phosphorylase activity. Biochem Biophys Res Commun. 1992; 184(3): 1311-6

Vezzoni P, Giardini R, Lombardi L, Rilke F, Lucchini R, Vezzoni MA, Clerici L. Multienzymatic analyses of human malignant lymphomas; Correlation of enzymatic data with pathologic and ultrastructural findings in Burkitt's and lymphoblastic lymphomas. Cancer 1984: 54(3): 489-99

Yoshida M, Fujisawa J, Positive and negative regulation of HTLV-1 gene expression and their roles in leukemogenesis in ATL. In: Takatsuki K, Hinuma Y, Yoshida M, eds. Advances in adult T-cell leukemia and HTLV-1 research. Japan Scientific Societies Press, Gann Monograph on Cancer Research No. 39. 1992; 217-236