

## A Pathological Study on Cerebral Lesions in Diver's *Decompression Sickness (DCS)*

Motoo KITANO<sup>1)</sup>, Atsushi URAGO<sup>2)</sup>, Ko HAYASHI<sup>3)</sup>, Mahito KAWASHIMA<sup>4)</sup>,  
Keisuke FUNAKOSHI<sup>5)</sup>, Kunio YAMADA<sup>6)</sup>, and Shin-ichiro TOKUFUJI<sup>7)</sup>

### Abstract

Histopathological analysis was done on brains of four autopsy cases of acute decompression sickness (DCS). The findings of the brains in four cases of acute DCS was summarized as follows: 1) marked engorgement of the meningeal veins with marked stasis of blood with or without presence of intravascular air bubbles, 2) marked edema of the cerebral parenchyma with perivascular hemorrhage, 3) pallor spots around the venules and blood capillaries in the brain, especially in the deeper cortex and subcortical white matter, and 4) relatively-sharply defined foci of edematous necrosis in the deep layer of the white matter of the cerebrum, especially in the periventricular layer.

As for the causes of the cerebral lesions in DCS, bubble embolization seemed to be the most important factor. Alteration of permeability of the blood vessels caused by trapping of very small bubble emboli should contribute significantly to the histogenesis of pallor spots. Pathological-anatomical analysis ascribed that the pathogenesis of focal edematous necrosis to marked disturbance of venous circulation due to bubble embolization with a superimposing severe shock. For the latter lesion of the brain, the etiology seemed identical with that of the spinal cord lesion in DCS with apparent disruptions in the circulation of veins in and around the spinal cord.

**Key words:** Decompression sickness (DCS), Cerebral lesions, Pallor spots, Edematous necrosis, Bubble embolism.

---

1) Department of Oral Pathology, Kagoshima University Dental School\* and Department of Critical Care Medicine, Kagoshima University Medical Hospital.

2) Department of Oral Pathology, Kagoshima University Dental School.

3) Hayashi Medical Hospital.

4) Kawashima Orthopedic Hospital and Department of Oral Pathology, Kagoshima University Dental School.

5) Department of Oral Pathology, Kyushu Dental College.

6) Undersea Medical Center, Japan Marine Self Defence Force.

7) Department of Clinical Pathology, Kyushu Rosai Hospital.

\* Address: Usuki-cho 1208-1, Kagoshima-shi, 890 Japan.

## Introduction

Decompression sickness (DCS) is an illness most frequently seen in divers and caisson workers. Highly dissolved air gasses in blood and tissues under hyperbaric environment become bubbles if the speed of reduction of the environmental pressure is too fast to be eliminated from the lungs.

Histopathologic studies on changes of the brain in autopsy cases of DCS have been studied only by few investigators <sup>1)5)6)</sup>. Accordingly, the exact mechanisms by which the brain is injured are still obscure. The conventional view would ascribe the tissue damage in DCS to arterial bubble embolization with a consequent obstruction of arterioles and blood capillaries <sup>6)</sup>.

Recently, another hypothesis has been proposed by Chryssanthou and associates <sup>1)</sup> from the results of their experimental work. They suggest that the vascular permeability of the brain can be altered by the action of chemical agents released in the course of reactions initiated by interface activity of the blood and air bubbles. This alteration of the vascular permeability will then cause some injurious changes of the brain.

We have already described in a previous paper <sup>9)11)12)</sup> the pathogenesis of the spinal cord damage in the autopsy cases of DCS and concluded that the circulatory disturbance of the venous system played an important role in the development and progression of the parenchymal changes.

This paper is based upon four autopsy cases of DCS of Japanese divers (Table). The purposes of this study are to describe the histopathologic changes of the brains and to discuss the pathogenesis of the cerebral lesions.

## Cases and Autopsy Findings

*Case 1:* A 38-year-old male helmet diver dived to a depth of 40 meters for four hours, and surfaced in 20 minutes. While surfacing, he lost his consciousness and expired soonafter.

Autopsy findings : At the time of autopsy, foamy blood with numerous air bubbles was flowing out from incised sites of the heart, vena cavae, portal veins of the omentum and mesenterium, and superficial veins of the brain. In addition, the blood seemed to be somewhat concentrated with an increased viscosity. Severe cyanosis was noted in the body surface. Extensive and marked congestion, edema, and intraalveolar hemorrhage were found in the lungs. The other visceral organs were also congested. There were many dilated sinusoids in the bone marrow tissue of the femur containing a characteristic vacuoles which were unstainable by all dyes used in our laboratory in the lumens of the sinusoids (Fig. 1).

The brain weighed 1,580 grams and showed a marked edematous swelling and congestion. Histologic examination disclosed marked erythrocytic stasis within the small blood vessels including the blood capillaries accompanied by a perivascular hemorrhage of the gray and white matters of the brain. Perivascular hemorrhage was widely seen in the brain stem including the midbrain, pons, and medulla oblongata. Coexistence of numerous pallor spots was another peculiar finding. Venules and/or blood capillaries were present in some of the localized pallor

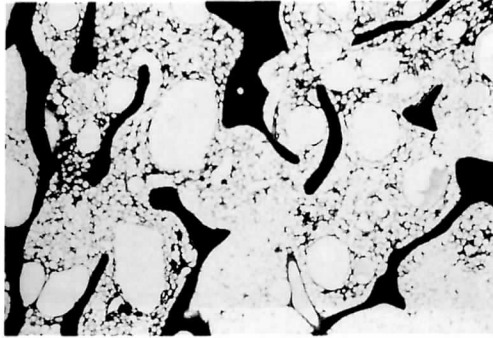


Fig. 1 : Characteristically dilated sinusoids suggesting lodgment of air bubbles of the bone marrow of the femoral head. Case 1. H-E  $\times$  130.

spots. Axons in the affected areas were spared. Nerve cells and glial cells underwent regressive changes. The spots tended to be scattered in the deeper cortex and also in the subcortical white matter.

The spinal cord also showed an edematous swelling. Perivascular hemorrhage was occasionally seen in the spinal cord parenchyma.

*Case 2:* A 28-year-old male scuba diver collecting shellfish at sea bottom of a depth of 40 meters. He repeated diving and surfacing seven times, and began complaining of dyspnea and numbness in his lower limbs immediately after the last surfacing. Approximately ten minutes later, he fell into a shock state. He expired in an ambulance eight hours after the onset of the symptoms.

Autopsy findings : Cyanosis was extensive and marked in the body surface. Although there were no visible air bubbles in the blood within the heart and large blood vessels at the time of autopsy, the synovial fluid within the joint cavities of the hip and knee was foamy containing numerous air bubbles. Marked congestion, edema and intraalveolar hemorrhage were observed in the lungs. In addition, the lungs showed a number of fat emboli within the intrapulmonary blood vessels. The bone marrow of the femoral shaft showed an extensive and marked foamy appearance with progressive necrotic changes. From these findings, it may be assumed that the bone marrow was an important tissue that served as a source of embolic fat in the lungs<sup>11)</sup>.

The brain weighed 1,500 grams and showed marked congestion and edema. Perivascular hemorrhage was also observed. Rarefaction of the parenchymal tissue and swelling of the astroglial cells occurred in some perivascular layers. The pallor spots seen in Case 1 were also present in a great many number in the deeper cortex and subcortical white matter (Fig. 2). Serial sections of the brain disclosed that the pallor spots were located around the blood capillaries or venules (Fig. 3). The axons were spared, and the nerve cells and glial cells were regressive in these areas.

The spinal cord was swollen with a marked edema and periventricular hemorrhage. These changes seemed to be closely related to a huge engorgement of the epidural veins around the spinal cord. Blood within the lumens almost entirely coagulated and contained a number of fat droplets<sup>11)</sup>.

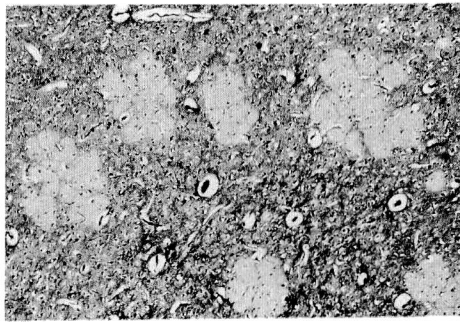


Fig. 2 : Innumerable pallor spots of the cortical gray matter and white matter of the frontal lobe of the cerebrum. The spots are difficult to be stained with various dyes used routinely in our laboratory. Case 2, PTAH  $\times 130$ .

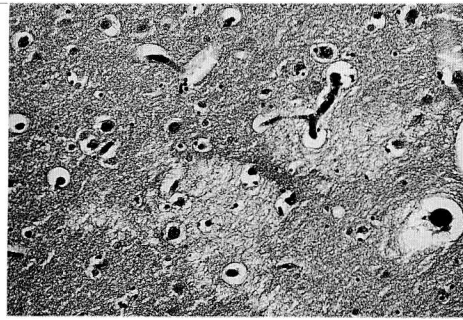


Fig. 3 : Larger magnification of pallor spots. A capillary runs in the affected area. Case 2, H-E  $\times 165$ .

Case 3: A 36-year-old male scuba diver four times to a depth of 60 meters for about 40 minutes each time accompanied by an interruption of 15 minutes. He complained of pains in both legs after surfacing from the last dive. He twice tried a conventional treatment (water again: fukashi) for his DCS. However, his symptoms never improved and repetitious vomiting occurred. About 20 hours later, he was transferred to a hospital. Physical examinations on the admission disclosed a complete sensory loss and flaccid paralysis of the bilateral lower extremities, as well as hypesthesia and weakness of muscular power of the bilateral upper extremities. Vesicorectal disturbance and slight dyspnea were also observed. He was then received into a recompression chamber and treated by recompression. When the atmospheric pressure inside the chamber raised to reach 5 ATA, he had a marked hematemesis and his general condition became worse. So, the recompression therapy had to be discontinued. The next morning he fell into a severe shock state and had a sustained high fever up to 42 degrees centigrade. He expired five days after the onset of the disease without any signs of recovery from the shock. The clinical diagnosis was DCS manifesting spinal cord damage with severe shock.

Autopsy findings : In gross inspection, there were no visible air bubbles in the blood within the blood vessels. Hemorrhagic and erosive esophagitis was found. Marked congestion, edema and aspiration of blood associated with marked traheobronchitis and slight bronchopneumonia were noted. A small number of thrombi and fat emboli were observed in the pulmonary vessels.

The other organs were markedly congested. The bone marrow of the right femoral head showed extensive necrosis and contained numerous air bubbles <sup>8)9)</sup>.

The spinal cord showed extensive areas of edema and necrosis, especially in the thoracic segments (Fig. 4)<sup>9)</sup>. The necrotic lesions trended to be limited to the lateral and posterior funiculi of the cord. There were several thrombi within the small veins in and around the affected areas.

The brain weighed 1,320 grams and showed marked congestion and moderate edema (Fig. 5). There were innumerable pallor spots up to 0.5 mm in the diameter around the blood capillaries and venules of the cerebral parenchyma, especially in the deeper cortex and subcortical white matter. Regressive changes in the nerve cells and glial cells in the affected areas were observed. Decrease in the number of Purkinje cells and the nerve cells in the granular layer of the cerebellar cortex was observed and was fully corresponded to the presence of a longstading severe anoxia due to shock. There were few number of thrombi in the small blood vessels of the brain. Perivascular hemorrhage was widely seen.

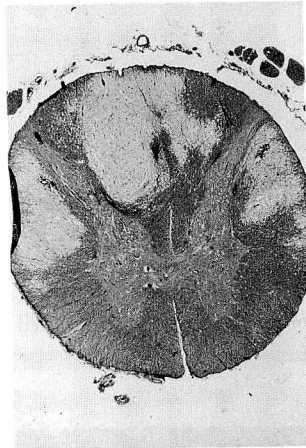


Fig. 4 : Ninth thoracic segment of the spinal cord showing extensive and marked edemaous necrosis. The lateral and posterior funiculi are particularly involved in the lesion characteristic to DCS. The gray matter is well preserved.  
Case 3, H-E  $\times$  8.

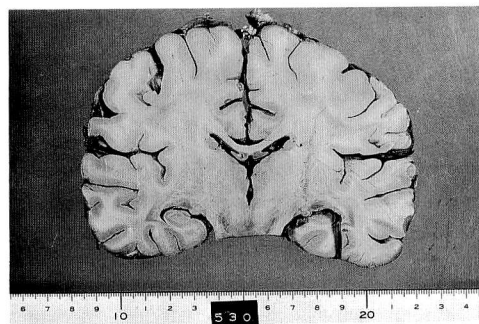


Fig. 5 : Cut surface of the brain of Case 3. Marked congestion of the super surface veins and moderate parenchymal edema are noted.

Several, small, up to 3 mm in diameter, relatively-sharply demarcated foci of necrosis were present in the deep layer of the white matter of the cerebrum, especially in the periventricular layer (Figs. 6,7,8,9). They showed tissue rarefaction with a marked edema. Destruction of the myelin sheaths and anomalous swelling of the axons were characteristic. Mesenchymal cell reaction was scarce in and around the necrotic focus, but slight hemorrhage was seen in the necrotic tissues. The necrotic foci seemed to be closely related to markedly dilated veins around the foci (Figs. 6,7,8). The lumens of these veins were empty suggesting lodgment of air bubbles which were occasionally entrapped and encircled by thrombotic material (Fig. 7). In some of the necrotic foci couples of capillaries containing thrombi were also present (Fig. 8).

Fat embolism was not observed by Oil-red-O staining applied on frozen sections of the cerebral tissue.

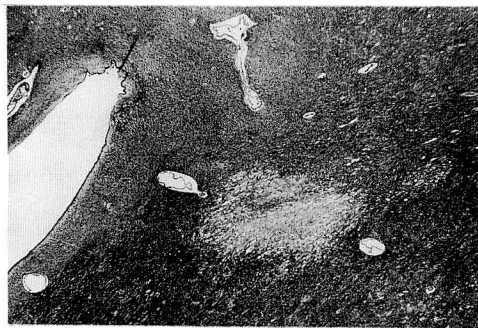


Fig. 6 : A periventricular focus of edematous necrosis. Dilated veins suggesting lodgment of air bubbles surround the focus. Case 3, H-E  $\times$  35.

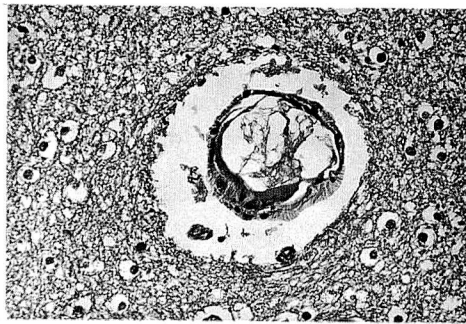


Fig. 7:: A vein containing vacuoles ( most possibly air bubbles ) enveloped by thrombi in the periphery of a necrotic focus. Axonal swelling is prominent in the perivascular layer. Case 3, H-E  $\times$  165.

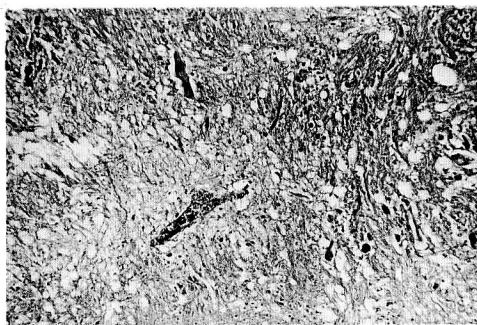


Fig. 8 : Capillaries with thrombi in and around a necrotic focus. Case 3, H-E  $\times$  100.

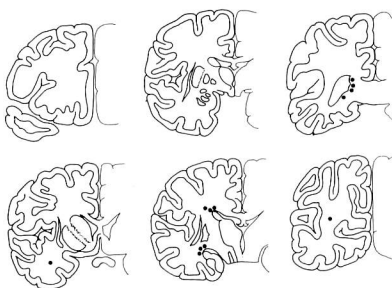


Fig. 9 : Schematic drawing of localization of the foci of edematous necrosis. Dark spots show

Case 4: A 20-year-old male scuba diver had a history of diving to a depth of 50 meters for 20 minutes. About 20 minutes after the surfacing, he complained of dyspnea and numbness of both legs and was transferred to a hospital. Physical examinations disclosed a complete sensory loss up to the 3-4th cervical dermatome. Pyramidal signs were seen in all the extremities showing flaccid paralysis and in the respiratory muscles resulting in inability of automatic respiratory movement. Vesicorectal disturbance was also noted. His consciousness was maintained in good condition and there was no cranial nerve dysfunction. He showed some improvement with recompression therapy. However, 14 days after the onset of the disease, he died of acute respiratory failure.

Autopsy finding : Intravascular air bubbles were not visible to the naked eye. Slight to moderate congestion was noted in the general visceral organs. Cystitis was marked. A small number of thrombi were found in the intrapulmonary blood vessels and the lungs showed slight bronchopneumonia. There was no detectable fat emboli in the lungs and other organs.

The brain showed marked congestion and edema, and weighed 1,575 grams. There were a relatively few pallor spots in the cerebral parenchyma, especially in the deeper cortex. Axonal and cellular damage in the affected areas was also noted. Very tiny foci of hemorrhage were scattered in the perivascular layers.

The spinal cord had an extensive and marked necrotic change with edema in the cervical and thoracic segments. The necrotic change was limited to the white matter of the cord, especially in the lateral and posterior funiculi. There were many thrombosed veins in and around the necrotic foci of the spinal cord and also in the epidural space of the vertebral canal<sup>9)</sup>.

## Discussion

The pathogenesis of cerebral damage in decompression sickness has been a subject of controversy. The conventional view would ascribe tissue damage to arterial bubble embolization with consequent obstruction of arterioles and blood capillaries<sup>6)</sup>. Recently another hypothesis was proposed that the venous obstruction leading to venous infarction would be the most causal factor for the development and progression of damage of various organs and tissues in DCS<sup>4)7)9)11)</sup>.

The common findings of the brains in four cases of decompression sickness in the present study can be summarized as follows ; 1) marked engorgement of the meningeal veins with a marked stasis of blood with or without presence of intravascular air bubbles, 2) marked edema of the cerebral parenchyma with perivascular hemorrhage, and 3) pallor spots around the venules and blood capillaries in the brain, especially in the deeper cortex and subcortical white matter.

The pallor spots seen around the blood capillaries and venules seemed to have resulted from an alteration of permeability of the blood vessels<sup>1)</sup>. The spots were small in size, and distributed in the deeper cortex and subcortical white matter. The size and location of the spots suggest that very small emboli which are almost-undoubtedly air bubbles should be trapped in the deeper cerebral cortex<sup>6)</sup>.

It is generally accepted that air bubbles are initially liberated from tissues and blood during decompression. The bubbles arising in the interstitium create tissue injury and also enter the circulation. Vascular permeability increases due to intimal damage by direct mechanical actions of intravascular bubbles resulting in plasma loss and interstitial edema. In the blood vessels, the air bubbles begin to exert direct mechanical effects such as bubble embolization, intimal damage, etc., and indirect effects due to surface activity at bubble-blood-interfaces. The bubble-blood-interaction as discussed by many researchers<sup>14)15)18)</sup> tends to alter the secondary and tertiary configuration of blood proteins, leading to an aggregation of blood platelets and an activation of the clotting system of blood and to release of vasoconstrictive substances, and finally to cause a disturbance of blood circulation due to increase of vascular permeability hemoconcentration, and intravascular coagulations of blood. When the air bubbles arising in the interstitium enter the circulation, other products of tissue and cellular disintegration, such substances as lipid, free fatty acids, peptides, histaminelike substances, potassium ion, etc. also enter. They all may play a role as agents of increase of vascular permeability together with intravascular air bubbles<sup>6)</sup>.

Another problem having to be considered and discussed is the development of multiple foci of edematous necrosis which are present in the deep layer of the white matter, especially in the periventricular areas. The foci were only seen in Case 3, and there has been no report of such a case of DCS revealing focal edematous necrosis of the brain in world literature. However, it seemed to be a very important event in DCS. The associated findings were a considerable number of veins and venules containing thrombi or dilating with an empty lumens suggesting the lodgment of air bubbles in and around the necrotic foci.

We previously reported that the spinal cord damage in DCS is caused by severe circulatory disturbance, especially by reduction of venous return from the spinal cord parenchyma<sup>9)11)</sup>. The histopathologic features in the spinal cord in DCS are very much akin to the change in the brain of



Case 3, that is the necrosis associated with marked edema. Edematous necrosis seems to be created from venous obstruction, rather than arterial obstruction<sup>9)13)15)</sup>. There appears to be an intimate topographic correlation of vascular changes of the veins and venules with perenchymal lesions of the spinal cord in DCS. Therefore, pathogenesis of the cerebral lesions in DCS may be also the same as that of spinal cord lesions, in which dyschoric changes of veins and blood capillaries of venous side contribute to the parenchymal changes.

The next problem is how the air bubbles reach the medullary blood vessels, and stagnate for a long time within them. It is generally accepted that air bubbles are initially liberated from tissues and blood during decompression. Bubbles arising in the interstitium also enter the circulation. The lipid-rich tissues of the central nervous system including the cerebrum is a predictable site of creation of intraparenchymal air bubbles, because the solubility of nitrogen gas in the lipid-, and lipid-rich tissues is much higher than in the non-fatty tissues<sup>2)3)18)</sup>. The fibrin thrombi seen in and around the necrotic foci of this case seemed to be closely associated with intravascular air bubbles. The fibrin thrombi should contribute to the stagnation of the air bubbles within the lumen of the blood vessels<sup>10)</sup>. However, it must be remembered that the present case affected by a longstanding severe shock before the death. The retardation of the venous return from the deep layer of the brain must be aggravated through right cardiac failure due to severe shock.

Although many hypothesis are proposed in the literature on the pathogenesis of the tissue damage in decompression sickness, the following two mechanisms seem most important ; 1) direct tissue damage by the autochthonous bubble formation in the parenchyma<sup>2)6)7)</sup>, and 2) indirect tissue damage due to the circulatory disturbance<sup>1)4)8)16)</sup>. Distribution of the parenchymal change in the Case 3 was restricted to the area around the veins and venules. Such a distribution of the parenchymal lesions seems to be incompatible with only the direct action of autochthonous air bubbles to the parenchyma. Thus, the present study supports the later possibility.

In conclusion, as for the causes of the cerebral lesions in DCS bubble embolization is the most important factor. Alteration of permeability of the blood vessels and the activation of blood clotting system contribute significantly to the histogenesis of cerebral lesions. When marked disturbance of the venous return occurs, the deep layer of the white matter especially the periventricular areas tend to be affected by focal edematous necrosis. For such lesions of the brain, the pathogenesis seems identical with that of the spinal cord lesions in DCS with apparent circulatory disturbance of the venous system.

### Acknowledgements

We are grateful to Prof. Riki Okeda (Dpt. Neuropathol., Med. Res. Inst., Tokyo Med. Dent. Univ.) for invaluable advice and discussions concerning this work. We also thank Dr. Charles E. Lehner (Dpt. Preventive Med., Wisconsin-Madison Univ. Med. School) for a critical reading of this manuscript.

## References

- 1) CHRYSSANTHOU, C., et al., 1977. Blood-brain and blood-lung barrier alteration by dysbaric exposure. *Undersea Biomed. Res.*, 4: 117-129.
- 2) FRANCIS, T. Jr., et al., 1988. Is there a role for the autochthonous bubble in the pathogenesis of spinal cord decompression sickness? *J. Neuropathol. Exp. Neurol.*, 47: 457-487.
- 3) GERSH, I., et al., 1944. Tissue and vascular bubbles after decompression from high pressure atmospheres — Correlation of specific gravity with morphological changes. *J. Cell Comp. Physiol.*, 24: 35-70
- 4) HALLENBECK, J. M., et al., 1975., Mechanisms underlying spinal cord damage in decompression sickness. *Neurol.*, 25: 308-316.
- 5) HAYASHI, K., 1974. Clinical and experimental studies on decompression sickness (in Japanese, with English abstract). *Fukouka Acta Med.*, 65: 889-908.
- 6) HAYMAKER, W., 1957. Decompression sickness. In *Handbuch der speziellen pathologischen Anatomie und Histologie*. 13 Band. Nerven-system. ed. Olubarsch, F. Henke, R. Rossle. pp 1600-1672, Springer-Verlag, Berlin.
- 7) HILLS, B. A. and JAMES, P. B., 1982. Spinal decompression sickness : Mechanical studies and a model. *Undersea Biomed. Res.* 9: 185-201.
- 8) KAWASHIMA, M., et al., 1977. Histopathology of the early stage of osteonecrosis in divers. *Undersea Biomed. Res.*, 4: 409-417.
- 9) KITANO, M., et al., 1977. Three autopsy cases of acute decompression sickness — Consideration of pathogenesis about spinal cord damage in decompression sickness. *Orthop. Traumatol.*, 26: 269-276.
- 10) KITANO, M., et al., 1978. Experimental studies on decompression sickness — Consideration about hypercoagulability of blood decompression sickness. *Orthop. Traumatol.*, 27:653-658.
- 11) KITANO, M. and HAYASHI, K., 1981. Acute decompression sickness — Report of an autopsy case with widespread fat embolism., *Acta Pathol. Jpn.*, 31: 269-276.
- 12) KITANO, M., et al., 1987. Late manifestation of spinal cord lesions in decompression sickness : Histopathologic analysis of an autopsy case. *Underwater Hyperbaric Physiol.*, IX: 219-228.
- 13) OKEDA, R., and SHIBATA, T., 1973. Radiation encephalopathy. *Acta Pathol. Jpn.*, 23: 867-883.
- 14) PHILP R. B., 1972. Interactions between gas bubbles and components of blood : Implications in decompression sickness. *Aerospace Med.*, 43: 946-953.
- 15) SUZUKI, K., et al., 1984. Vascular changes of Methotrexate-related disseminated necrotizing leukoencephalopathy. *Acta Neuropathol. (Berl)*, 65: 145-149.
- 16) TAKAGI, M., and MANO, Y., 1982. Acute decompression sickness — Report of an autopsy case. *Bull. Tokyo Med. Dent. Univ.*, 29: 71-76.
- 17) VERNON, H. M., 1907. The solubility of air in fats, and relation to caisson disease. *Proc. Roy. Soc. London*, 79:366-371.
- 18) WARREN, B. A., 1973. The ultrastructural morphology of air embolism : Platelet adhesion to the interface and endothelial damage. *Brit. J. Exp. Pathol.*, 54: 163-172.

Table : Four Autopsy Cases of Acute Decompression Sickness in male divers

Age	Profession	Duration of illness	Clinical Diagnosis
Case 1 38 yrs	helmet diver	0 hrs	Chokes
Case 2 28 yrs	scuba diver	8 hrs	Chokes (+ spinal cord injury?)
Case 3 36 yrs	scuba diver	5 days	Spinal cord injury with severe shock
Case 4 20 yrs	scuba diver	14 days	Spinal cord injury (died of acute respiratory failure)

(Accepted November 6, 1989)